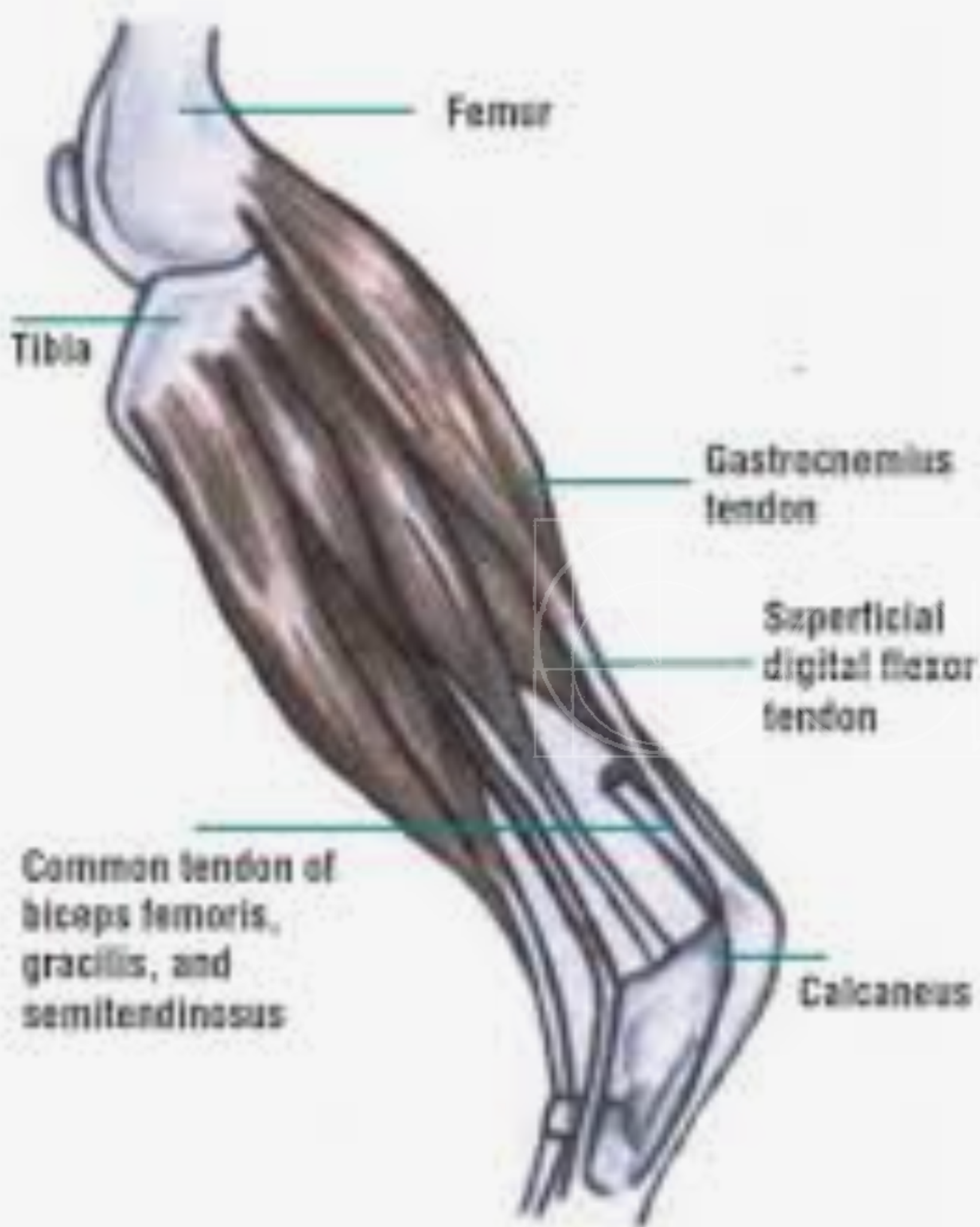

Tendón calcáneo común

Algunos detalles sobre el diagnóstico y tratamiento , dos casos clínicos

MENESCAL

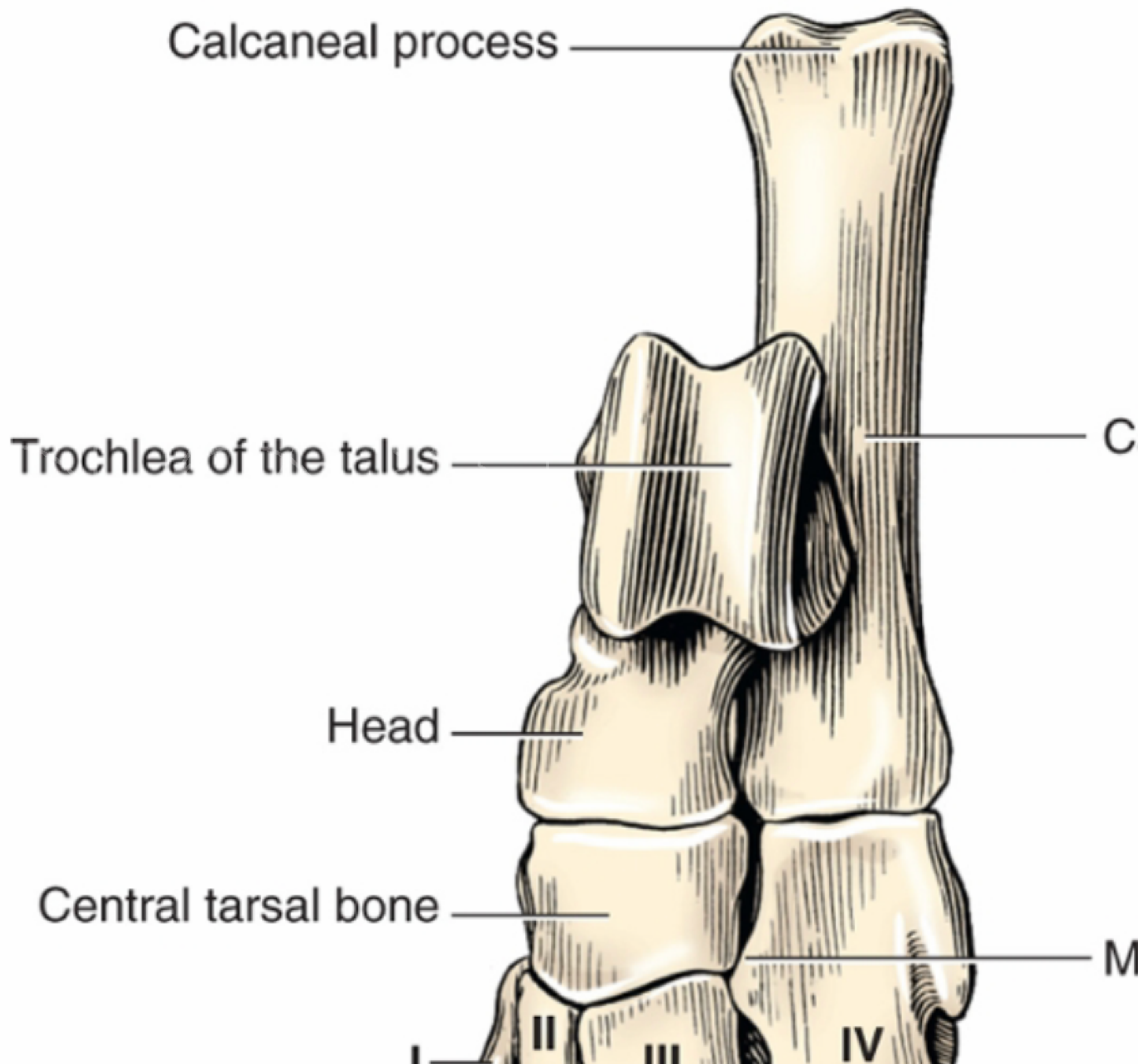
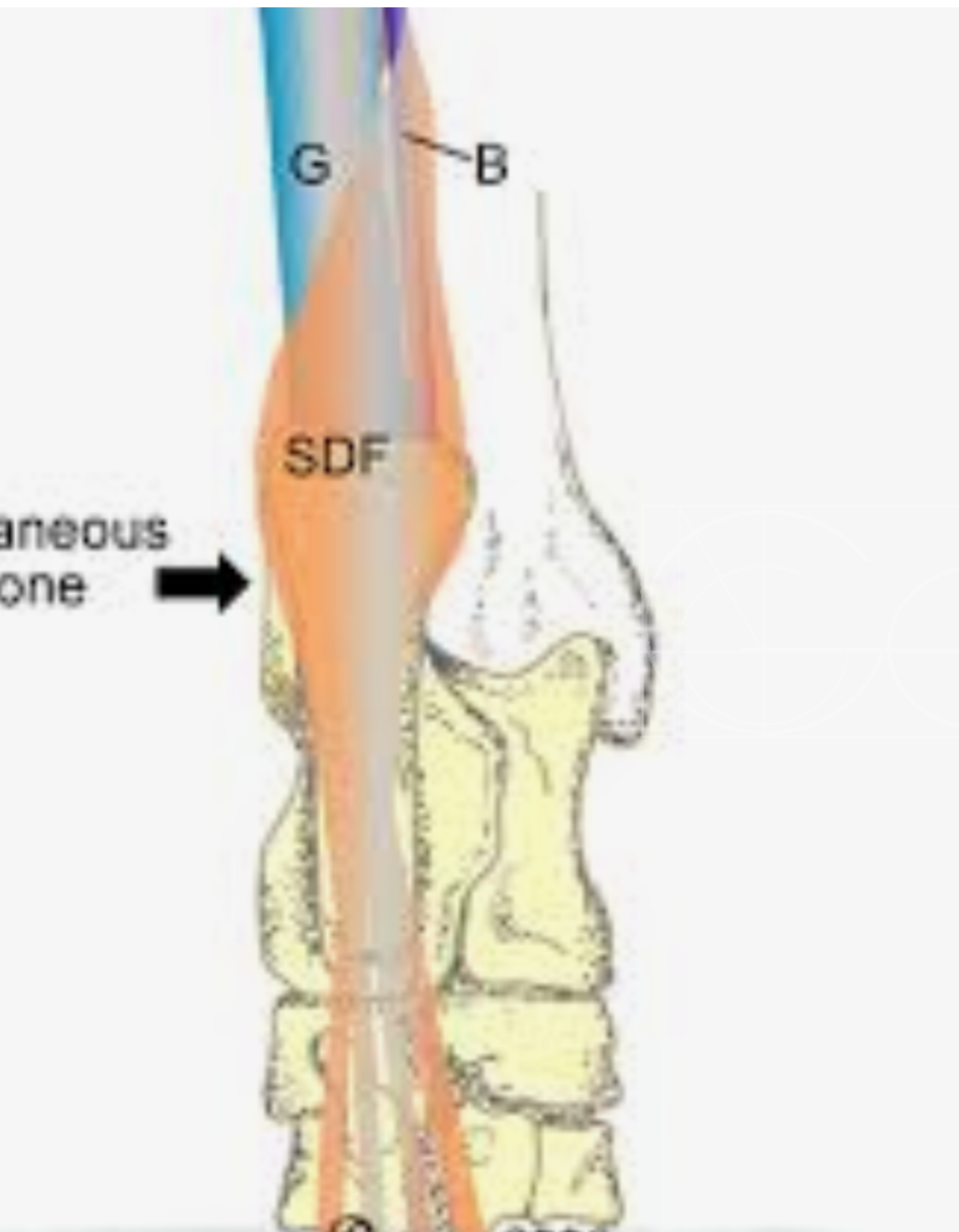
HOSPITAL VETERINARIO

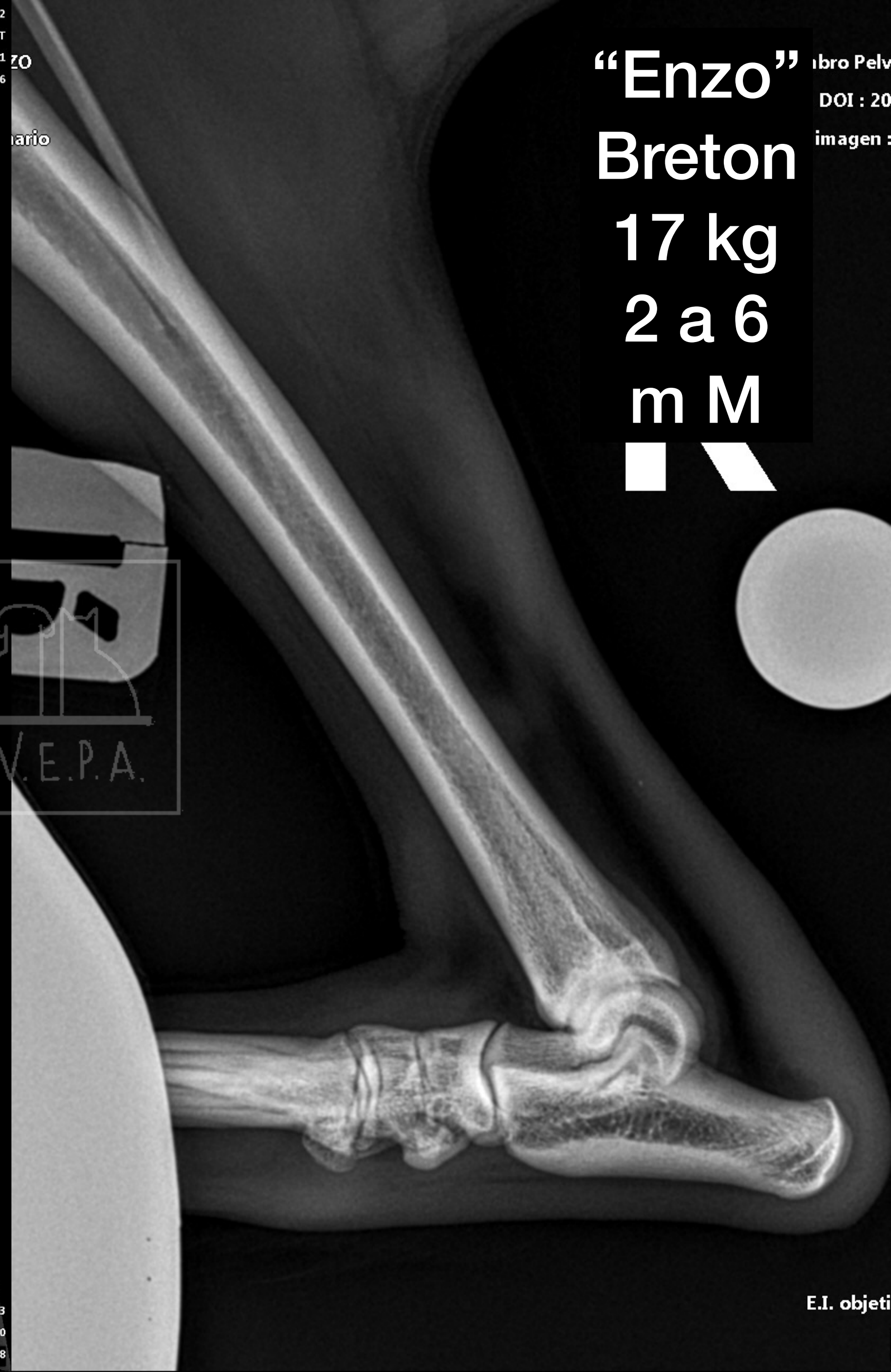
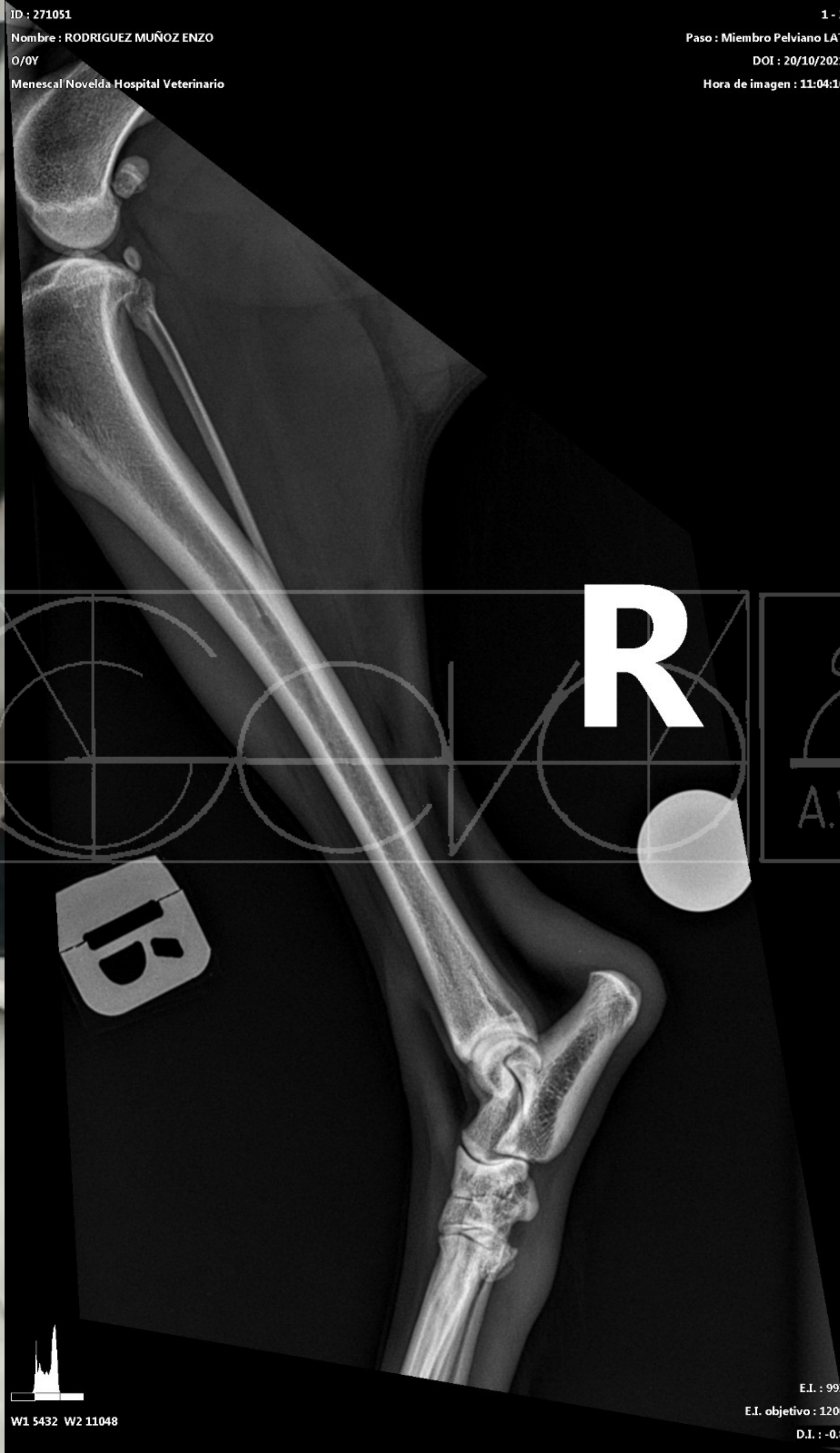

The common calcanean tendon (Achilles tendon) comprises three main parts:

- Paired tendons of the gastrocnemius muscle
- Combined tendon of gracilis, semitendinosus, and biceps femoris muscles
- Tendon of the superficial digital flexor muscle

Disruption^{54,66,76} can involve the entire tendon or can be seen in combinations of its component parts (recognized as a partial rupture). The two most common presentations include a traumatic rupture, which usually presents as a complete tear, and an atraumatic rupture, which often presents as partial





ID : 271051
Nombre : RODRIGUEZ MUÑOZ ENZO
O/0Y
Menescal Novelda Hospital Veterinario

1 - 2
Paso : Miembro Pelviano LAT
DOI : 20/10/2021
Hora de imagen : 11:04:16

“Enzo”
Breton
17 kg
2 a 6
m M

ibro Pelv
DOI : 20
imagen :

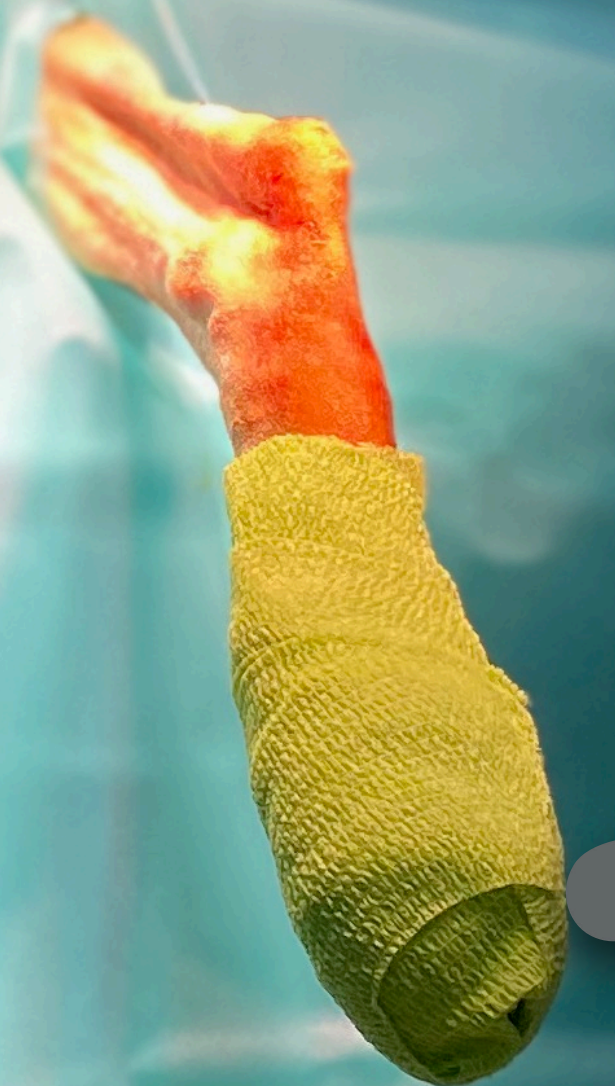r

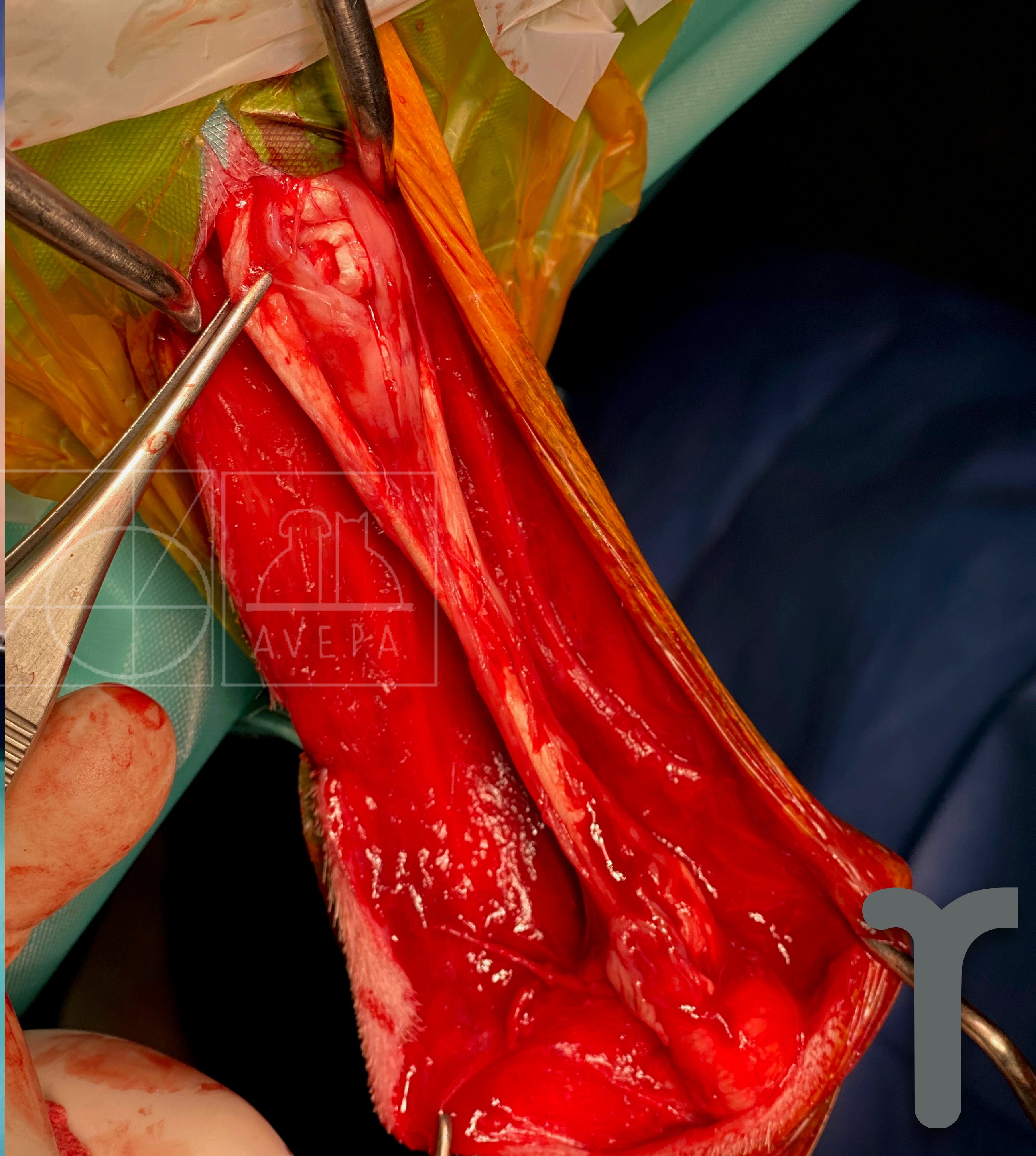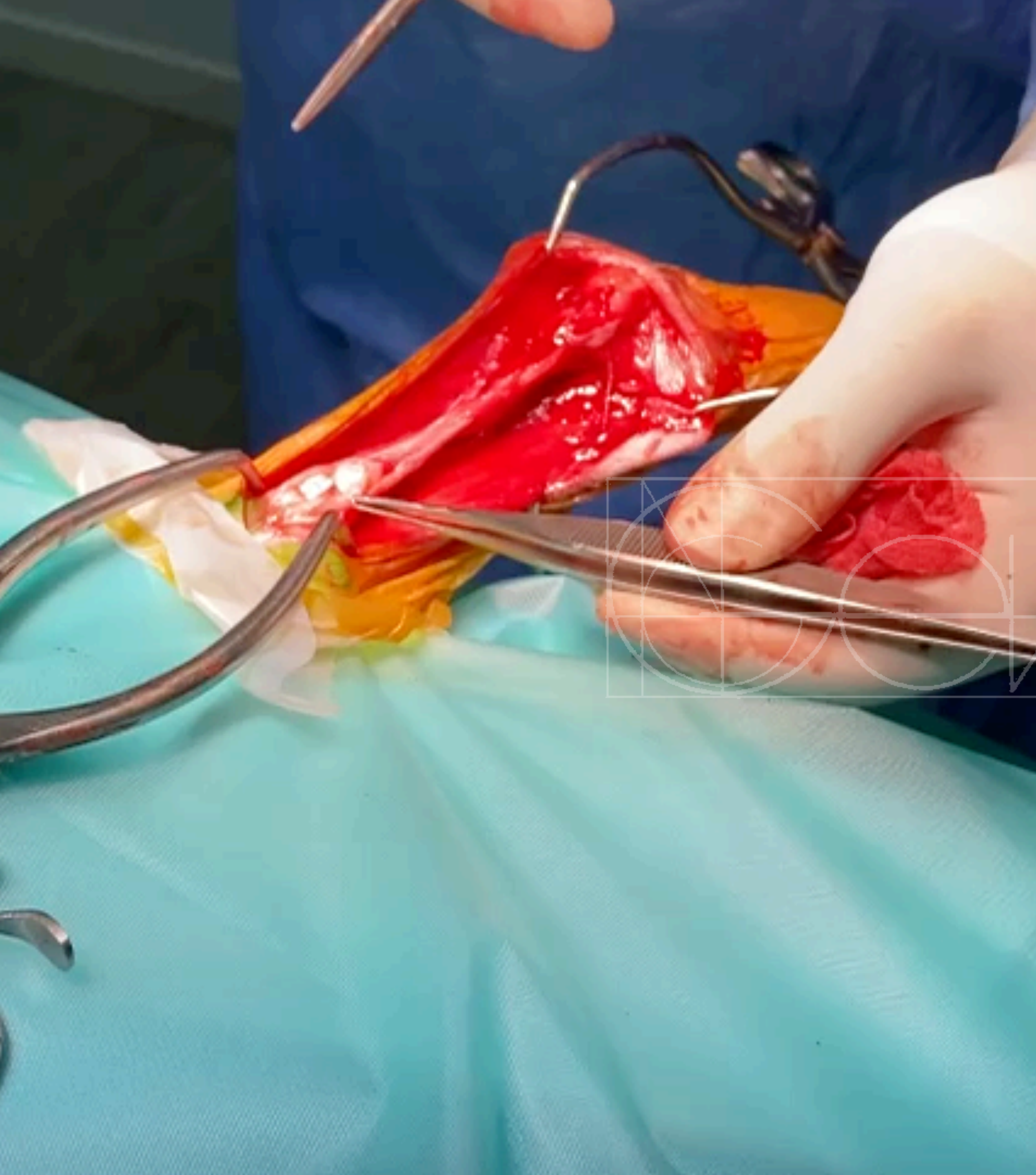
W1 5432 W2 11048

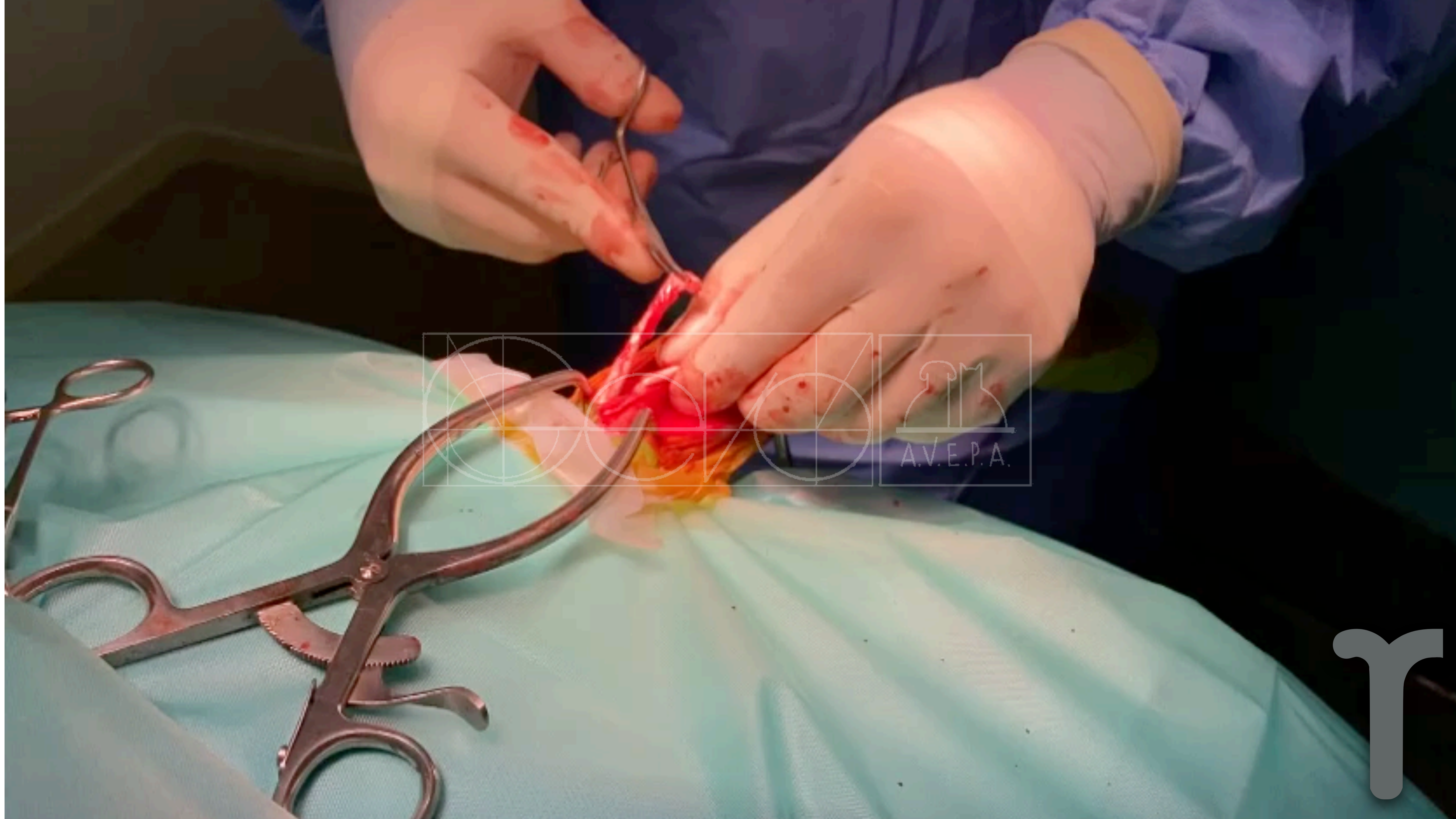
E.I. : 993
E.I. objetivo : 1200
D.I. : -0.8

E.I. objeti

**“Enzo”
Breton
17 kg
2 a 6
m M**





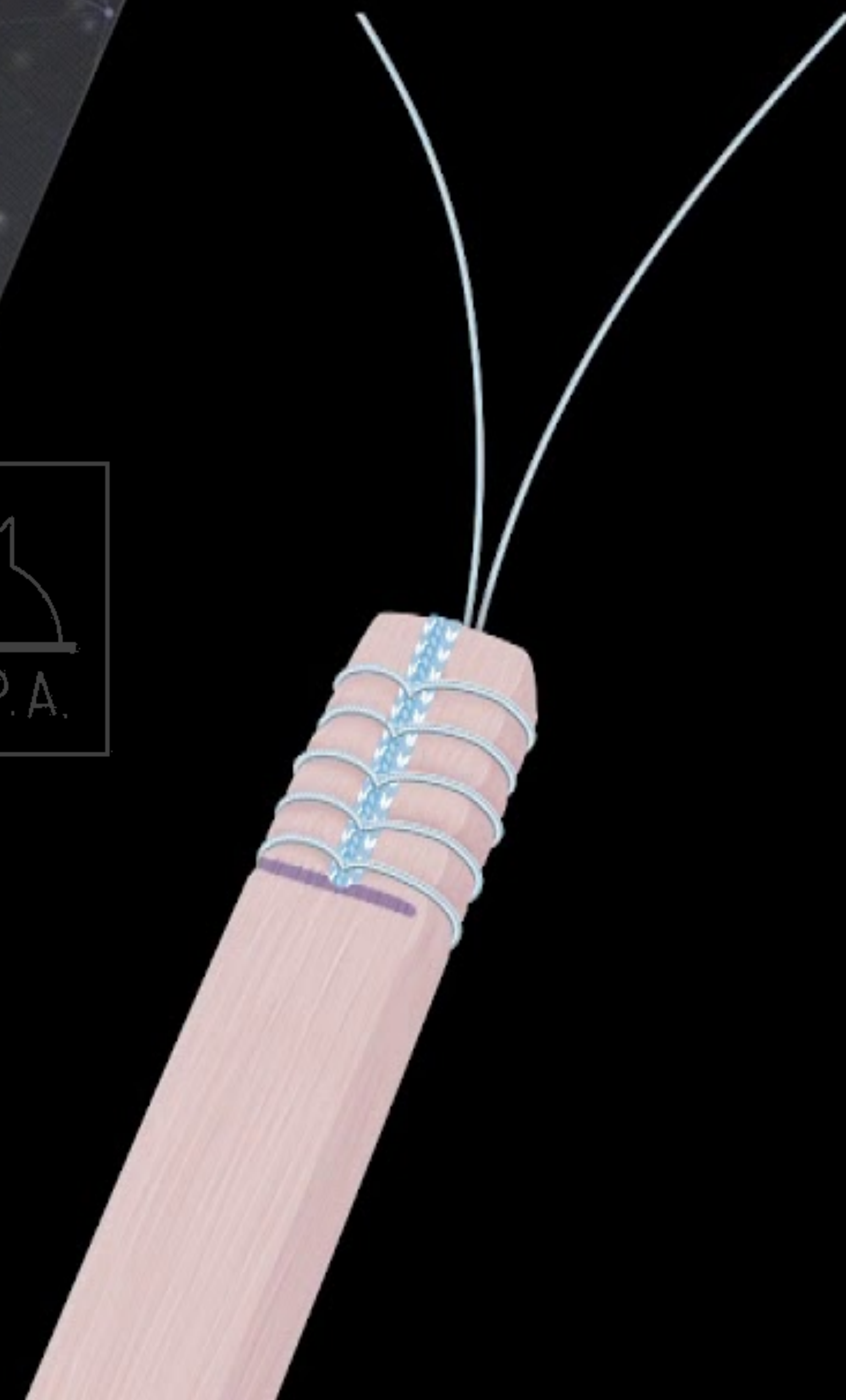


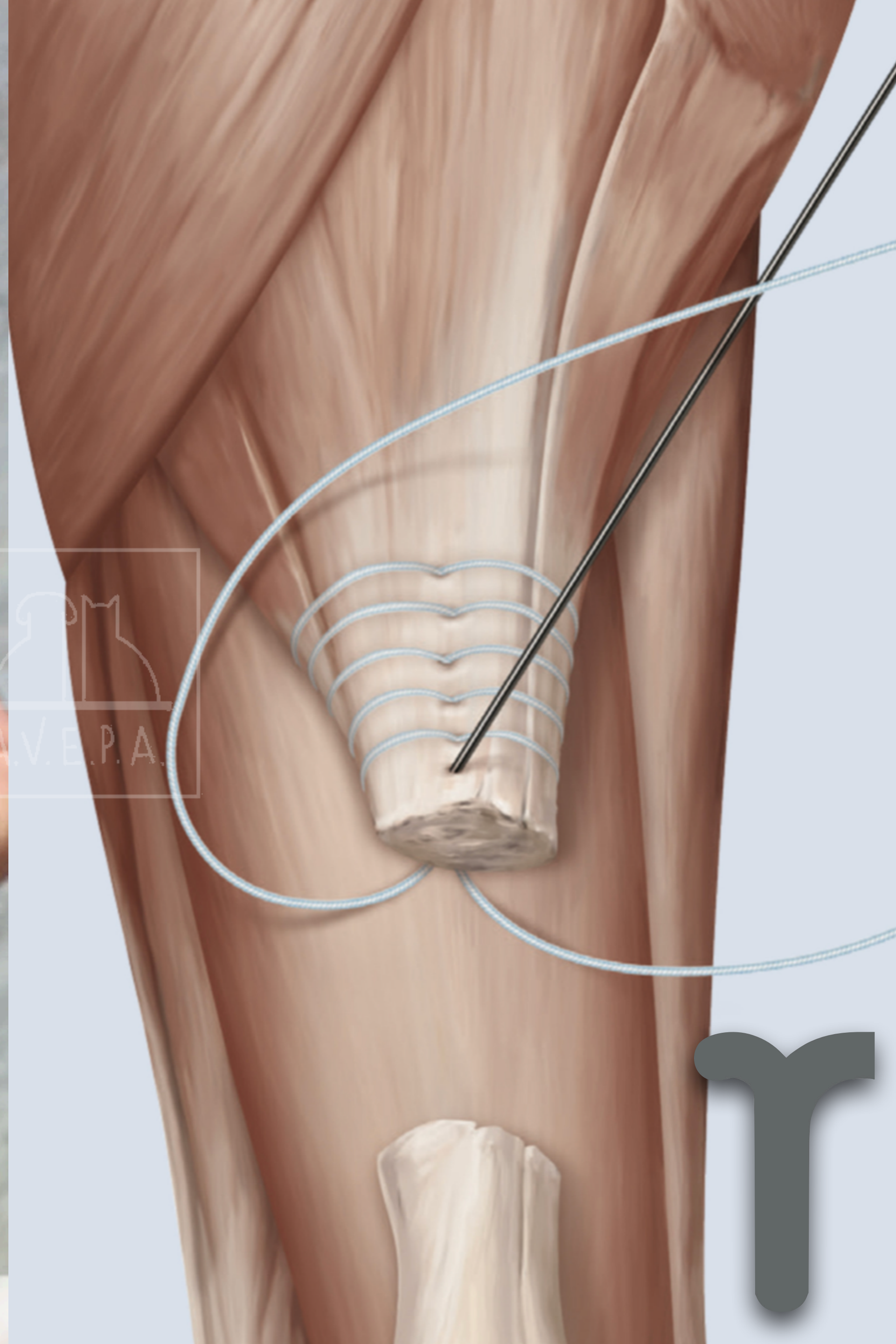

MODENA
A.V.E.P.A.

r

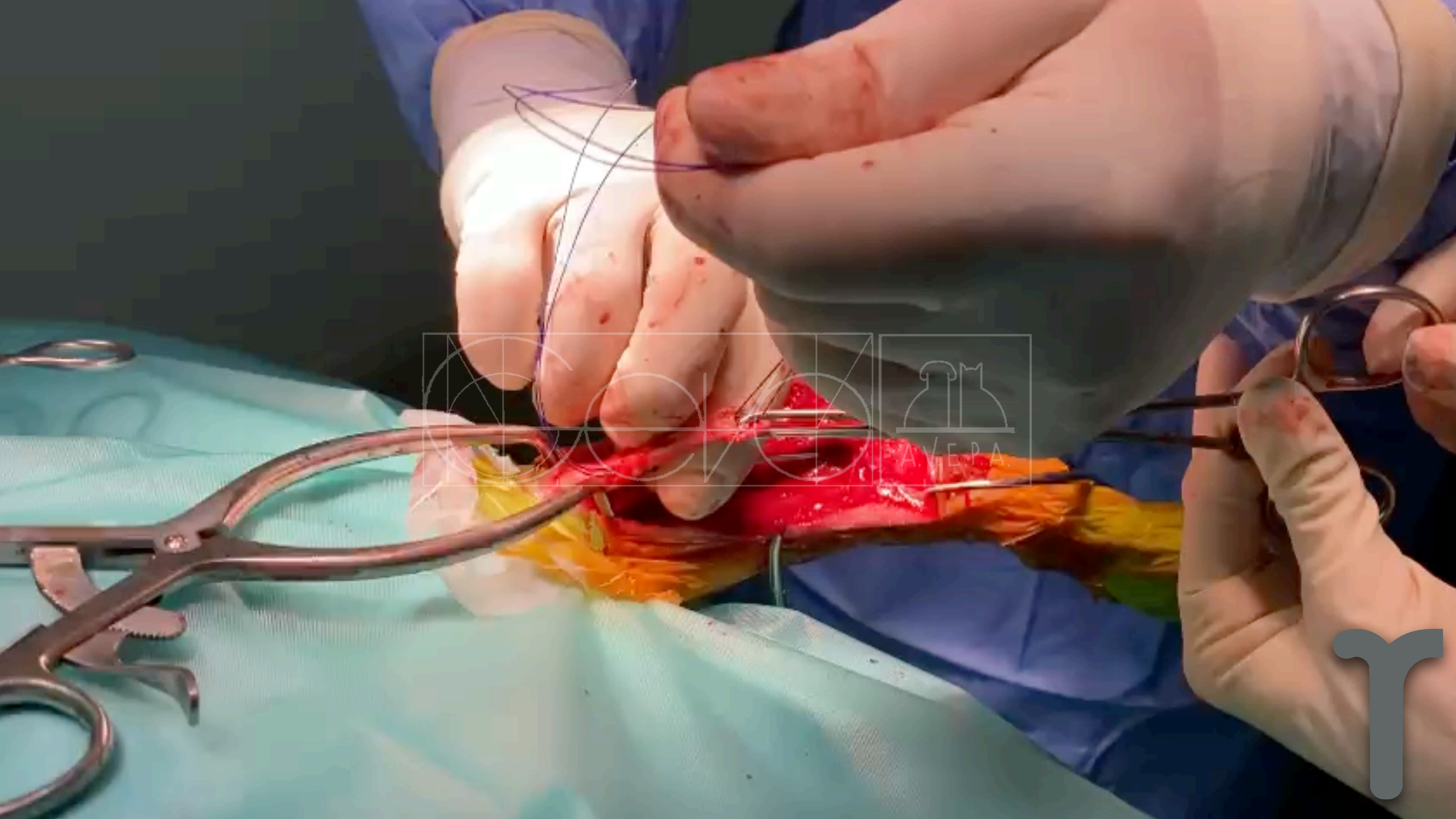


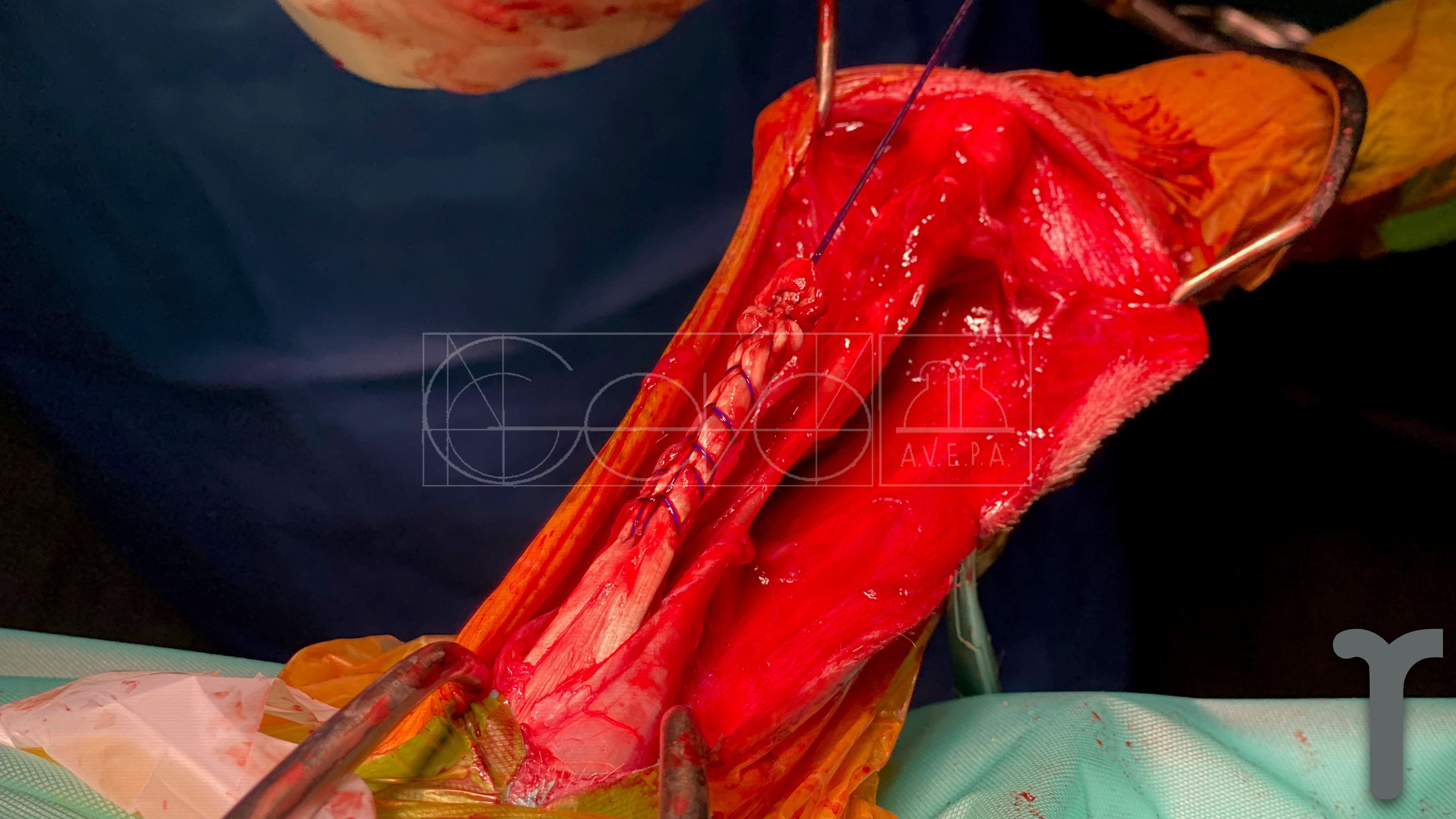
**SpeedWhip™ Rip-Stop Tendon Stitch
Using #2 FiberLoop® with FiberTag™**





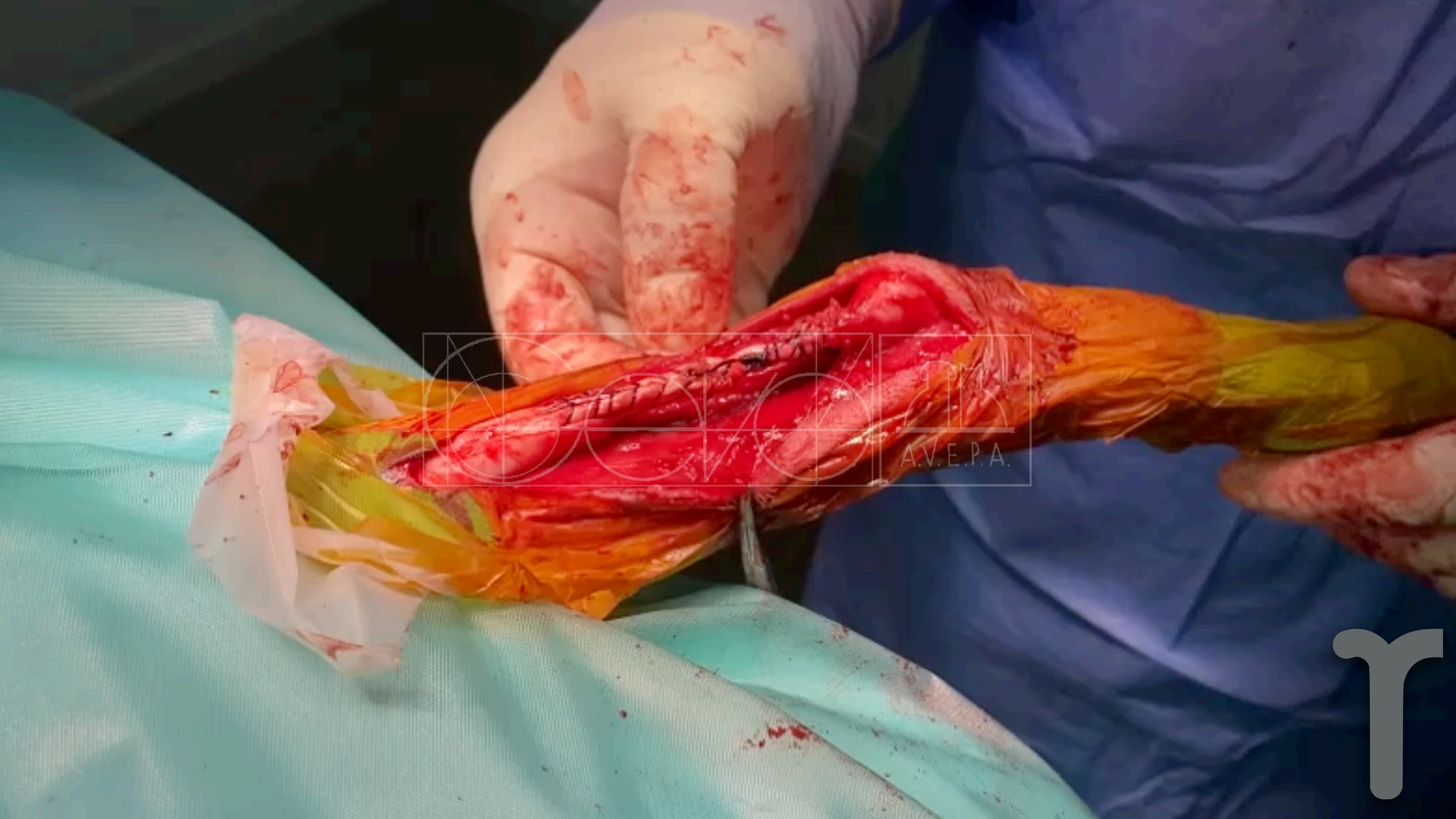
r





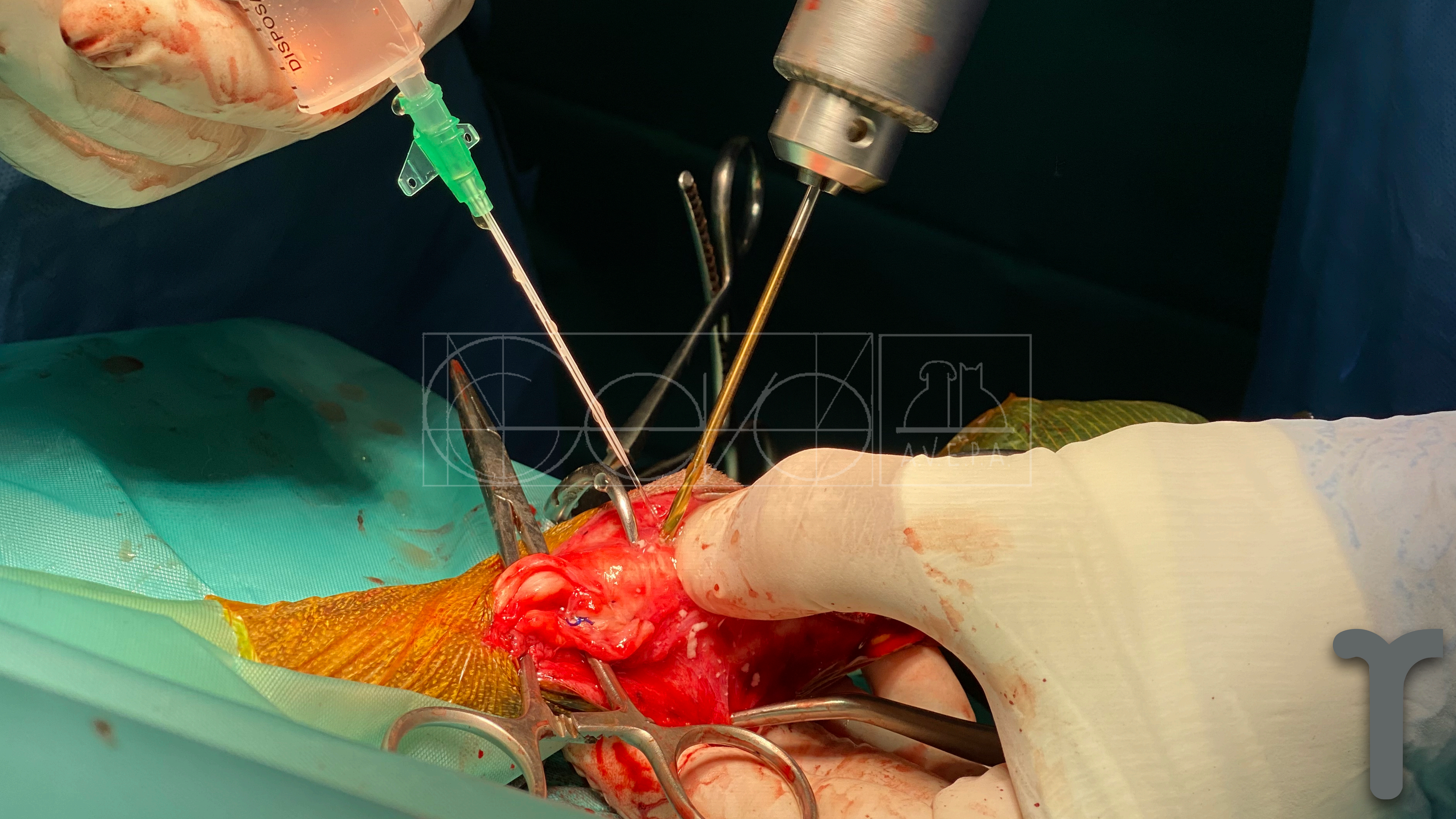
COLON
A.V.E.P.A.

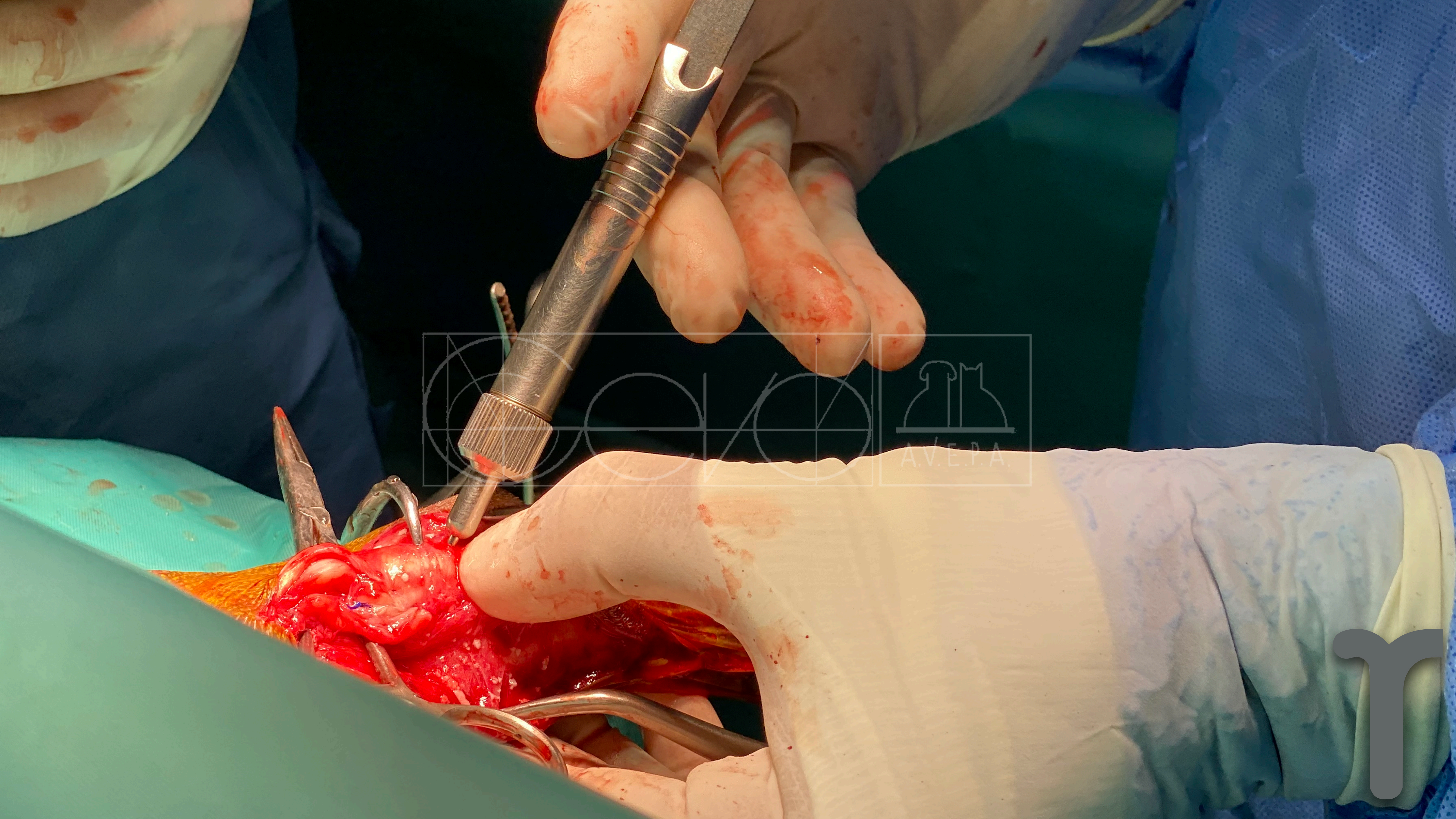
r



A.V.E.P.A.

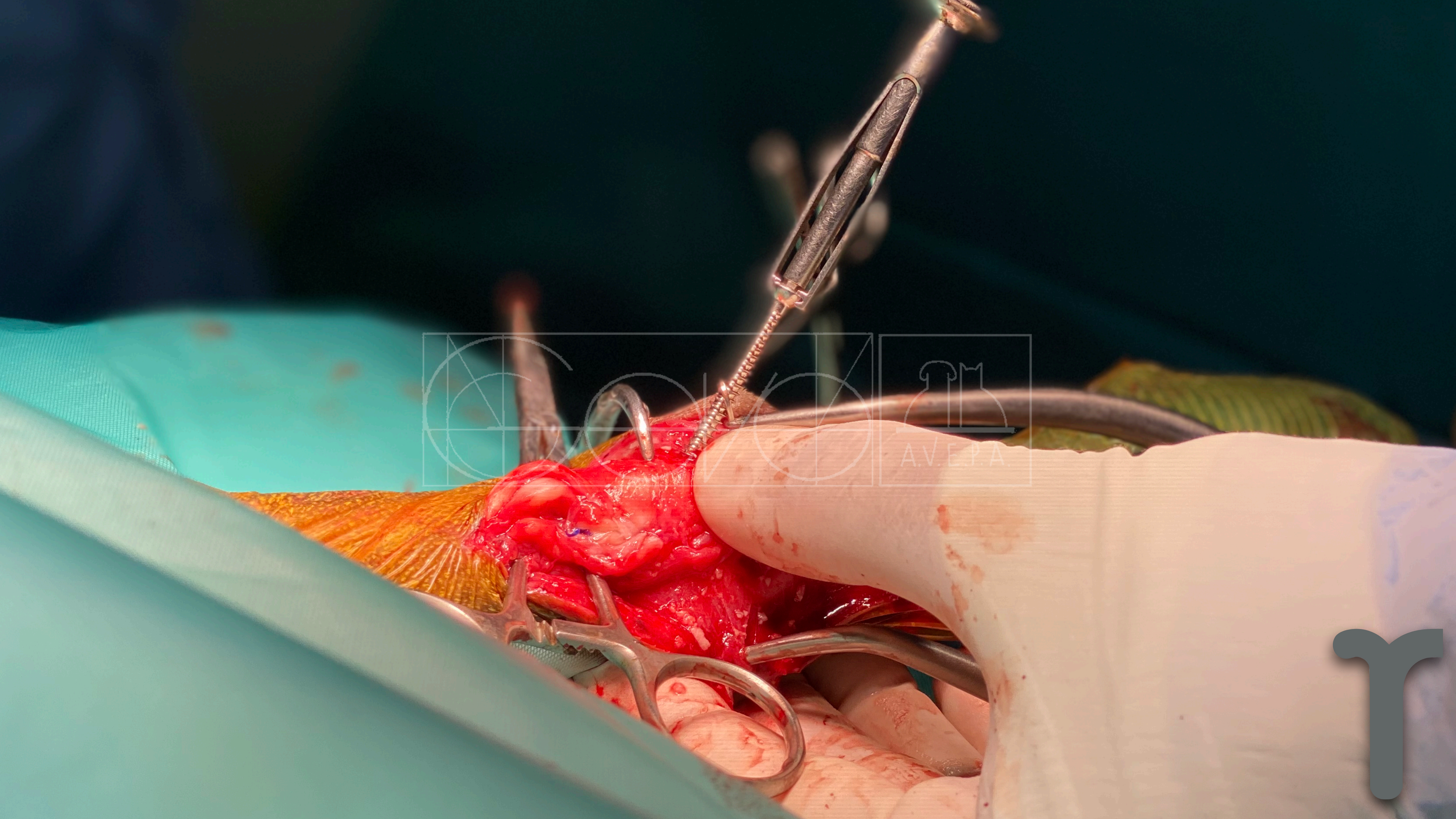
r

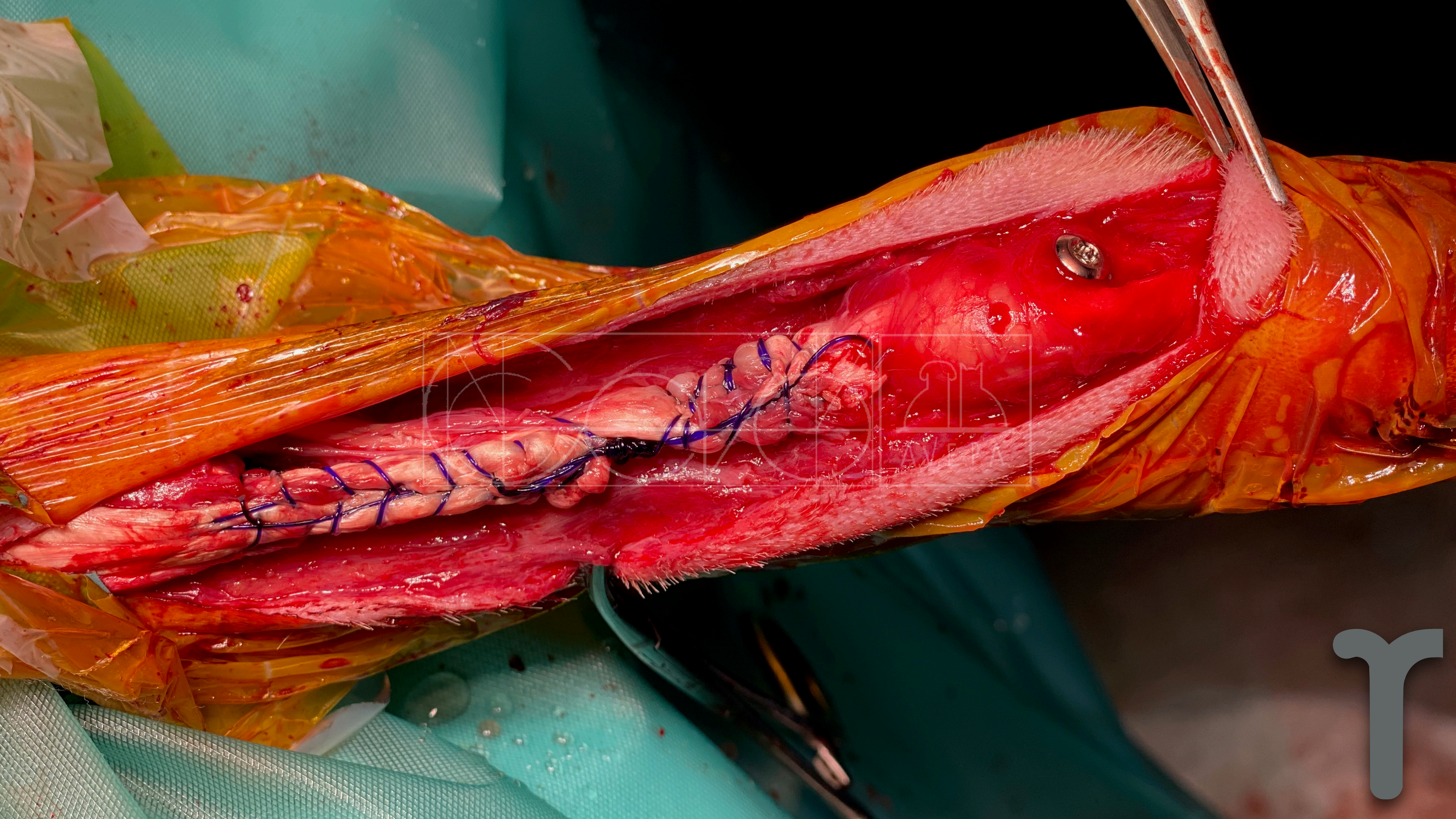



A.V.E.P.A.

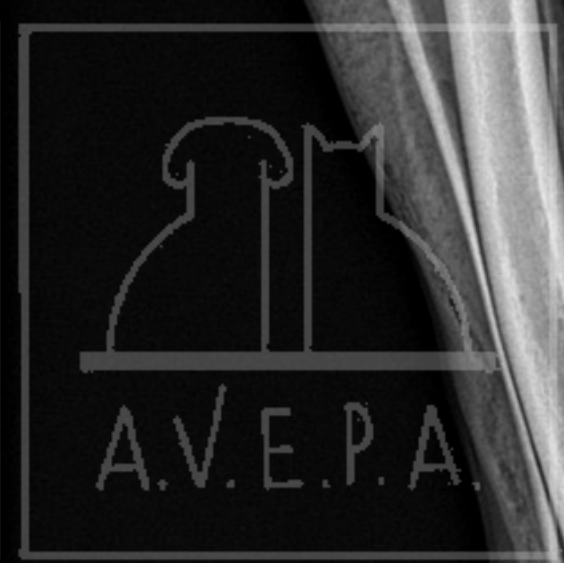
r





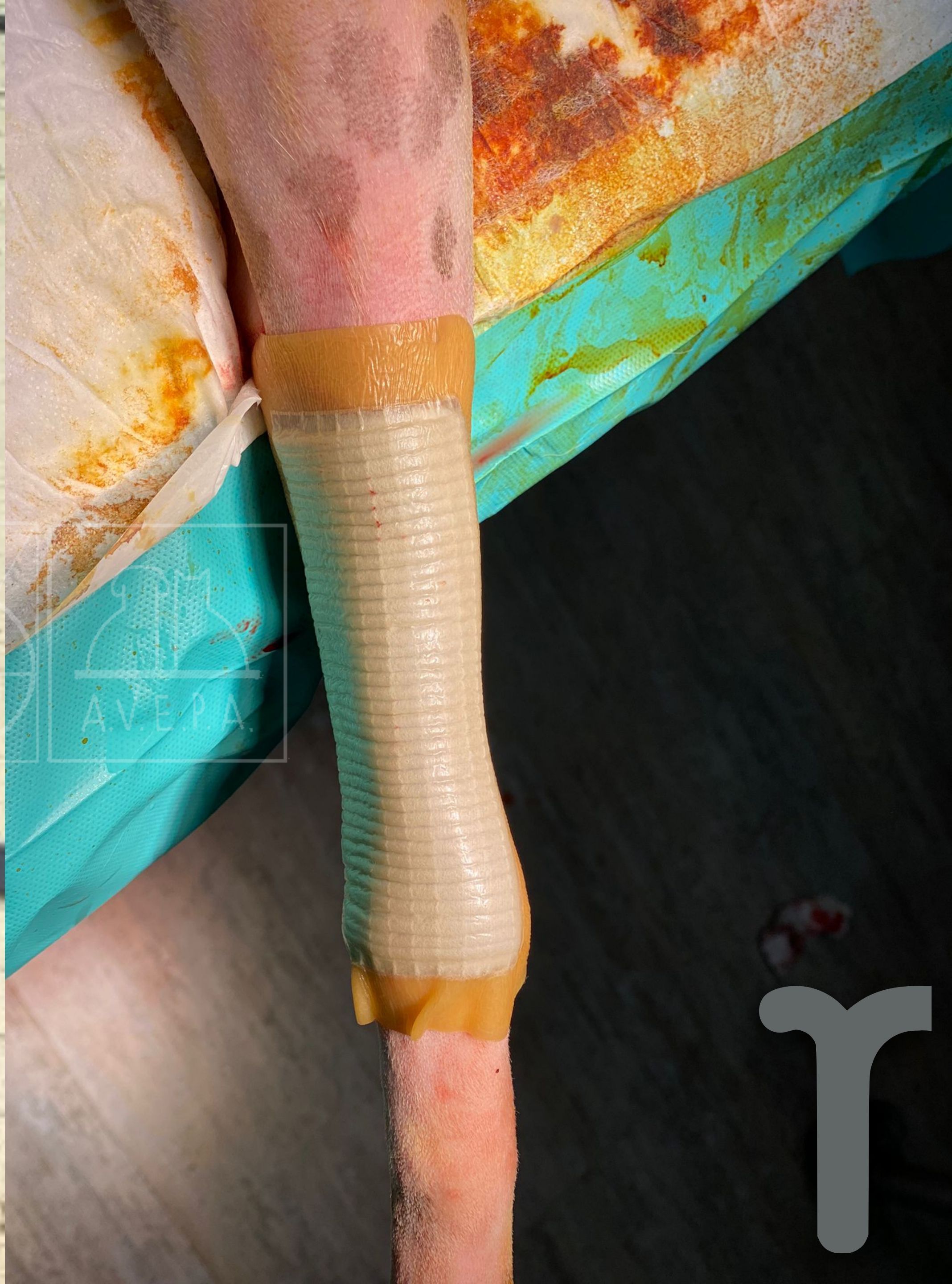R

“Enzo” Breton 17 kg 2 a 6 m M




R



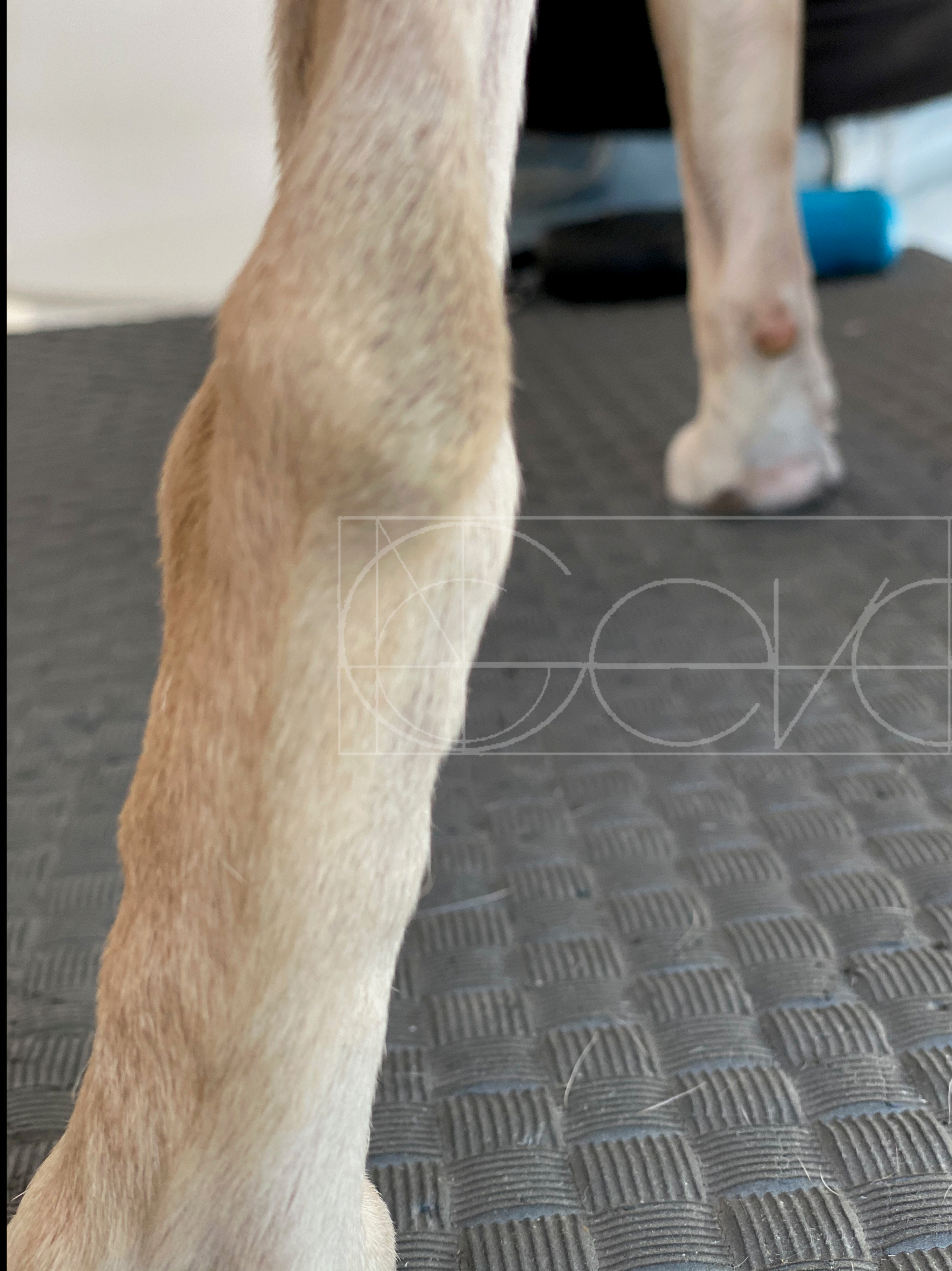

“Tokyo”
mestizo
11 kg 2
H

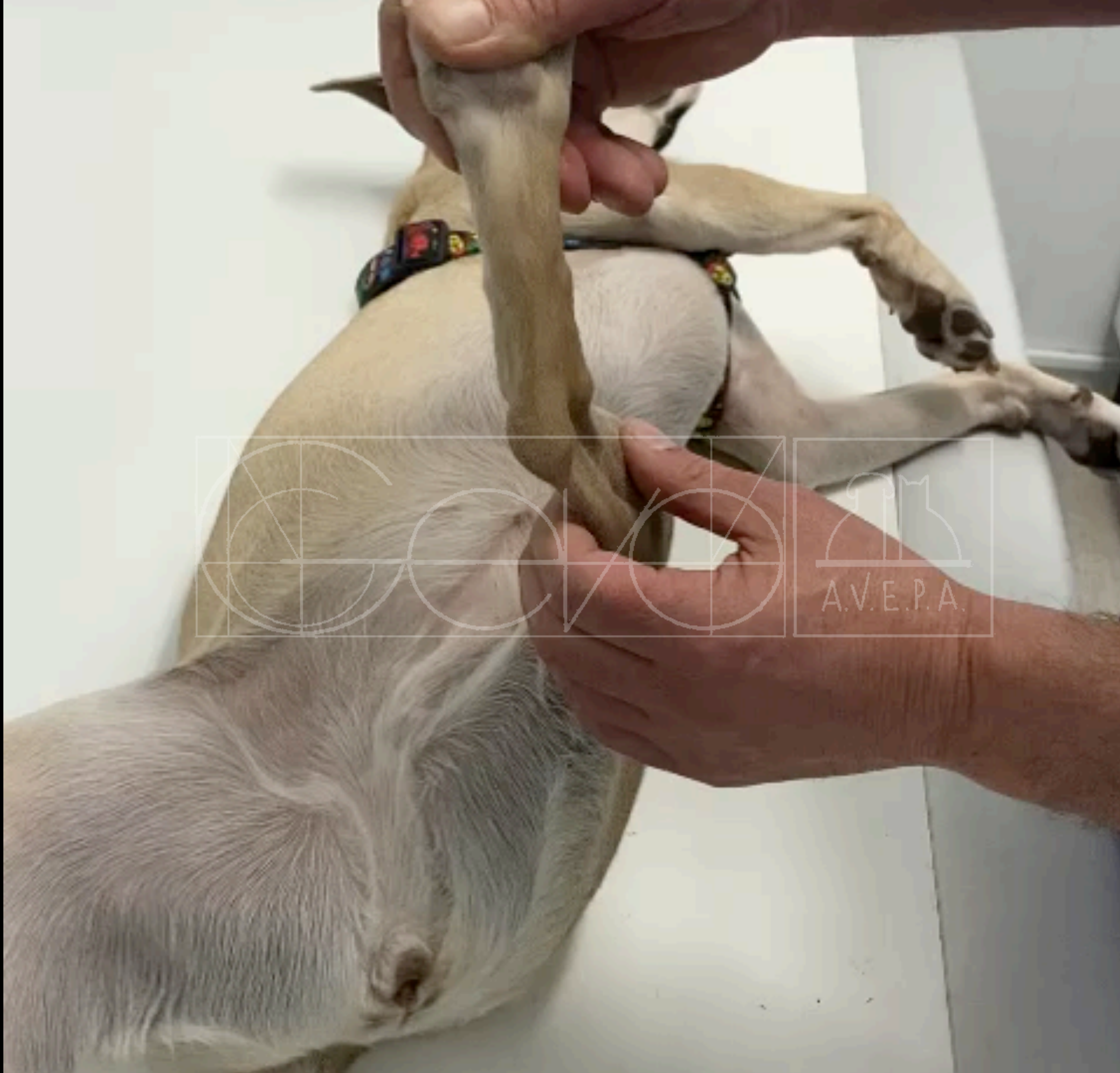

“Tokyo”
mestizo
11 kg 2
H





COVET
V.E.P.A.



D : 256134

1 - 7

Nombre : HERNANDEZ MARTINEZ TOKY Paso : Miembro Pelviano LAT

O/OY

DOI : 29/01/2021

Menescal Novelda Hospital Veterinario

Hora de imagen : 12:09:15

Nombre : HERNANDEZ IPaso : Miembro Pelviano LAT

O/OY

DOI : 29/01/2021

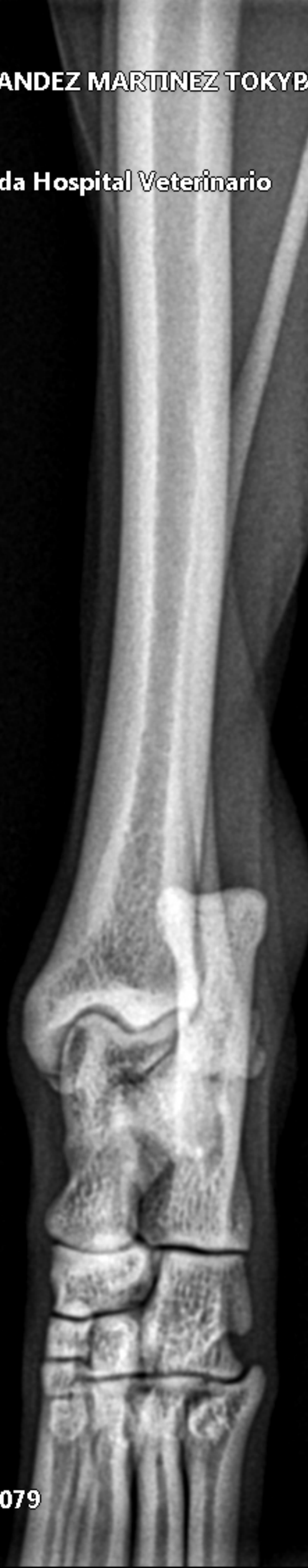Menescal Novelda Hospital Hora de imagen : 12:02:53

“Tokyo”
mestizo
11 kg 2
H

Paso : Miembro Pelviano

DOI : 29/01/2021

Hora de imagen : 12:02:53

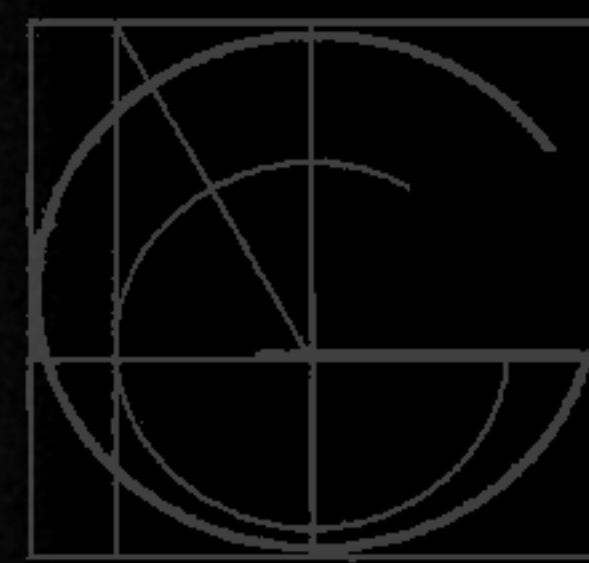


W1 5707 W2 11079

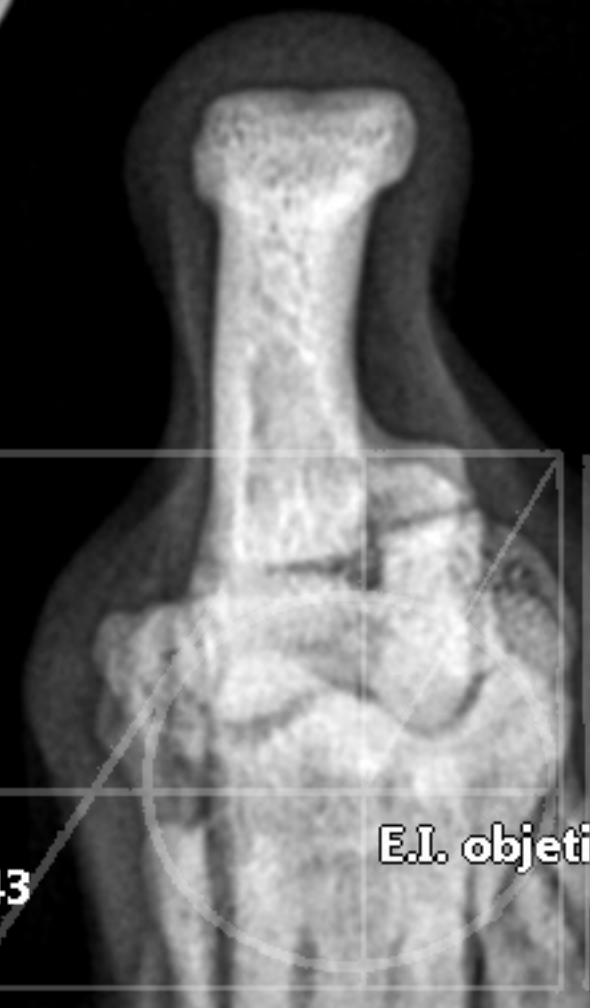E.I. : 301

E.I. objetivo : 1200

D.I. : -6.0




W1 5619 W2 10643




E.I. : 159

E.I. objetivo : 1200

D.I. : -8.8



W1 5478 W2 10655



E.I. objetivo

D.I.

J Small Anim Pract. 2020 Dec 21. doi: 10.1111/jsap.13288. Online ahead of print

1: Jury A. Surgical repair for luxation of the superficial digital flexor tendon using a temporary restraining pin. J Small Anim Pract. 2020 Dec 21. doi: 10.1111/jsap.13288. Epub ahead of print. PMID: 33346909.

2: Gatineau M, Dupuis J. Longitudinal tendon tear concurrent with bilateral medial luxation of the superficial digital flexor muscle tendon in a dog. Vet Comp Orthop Traumatol. 2010;23(4):289-93. doi: 10.3415/VCOT-09-05-0059. Epub 2010 Jun 21. PMID: 20585712.

3: McNicholas WT Jr, Wilkens BE, Barstad RD. Luxation of the superficial digital flexor tendon in a cat. J Am Anim Hosp Assoc. 2000 Mar-Apr;36(2):174-6. doi: 10.5326/15473317-36-2-174. PMID: 10730630.

4: Solanti S, Laitinen O, Atroshi F. Hereditary and clinical characteristics of lateral luxation of the superficial digital flexor tendon in Shetland sheepdogs. Vet Ther. 2002 Spring;3(1):97-103. PMID: 12050833.

5: Hoscheit LP. Luxation of the tendon of the superficial digital flexor muscle in two dogs. Can Vet J. 1994 Feb;35(2):120-1. PMID: 8069822; PMCID: PMC1686731.

1. MautererJV,PrataRG,CarberryCA,etal.Displace- ment of the tendon of the superficial digital flexor muscle in dogs: 10 cases (1983–1991). J Am Vet Med Assoc 1993; 203: 1162–1165.

2. Reinke JD, MughannamAJ. Lateral luxation of the superficial digital flexor tendon in 12 dogs. J Am Anim Hosp Assoc 1993; 29: 303–309.

3. Hoscheit LP. Luxation of the tendon of the superfi- cial digital flexor muscle in two dogs. Can Vet J 1994; 35: 120–121.

4. Bernard MA. Superficial digital flexor tendon in- jury in the dog. Can Vet J 1977; 18: 105–107.

5. Houlton JEF, Dyce J. Use of polypropylene mesh for revision of failed repair of superficial digital flexor tendon luxation in three dogs. Vet Comp Ortho Trauma 1993: 129–130.

6. Evans HE. Miller's Anatomy of the dog. 3rd ed. Philad- elphia, Pennsylvania, USA: Saunders; 1993. 369–370. 7. Roe SC. Injury and diseases of tendons. In: Bloomberg

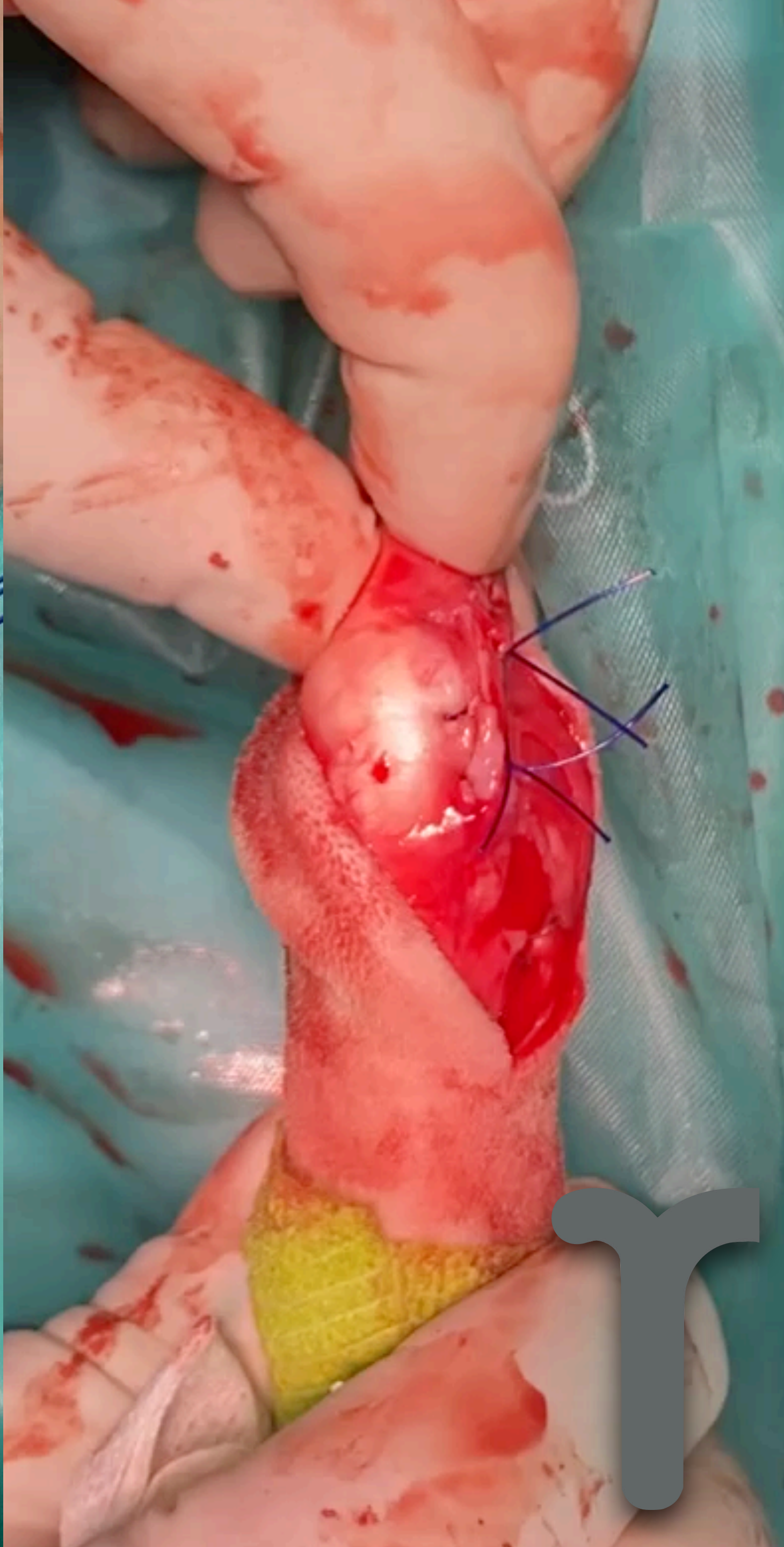
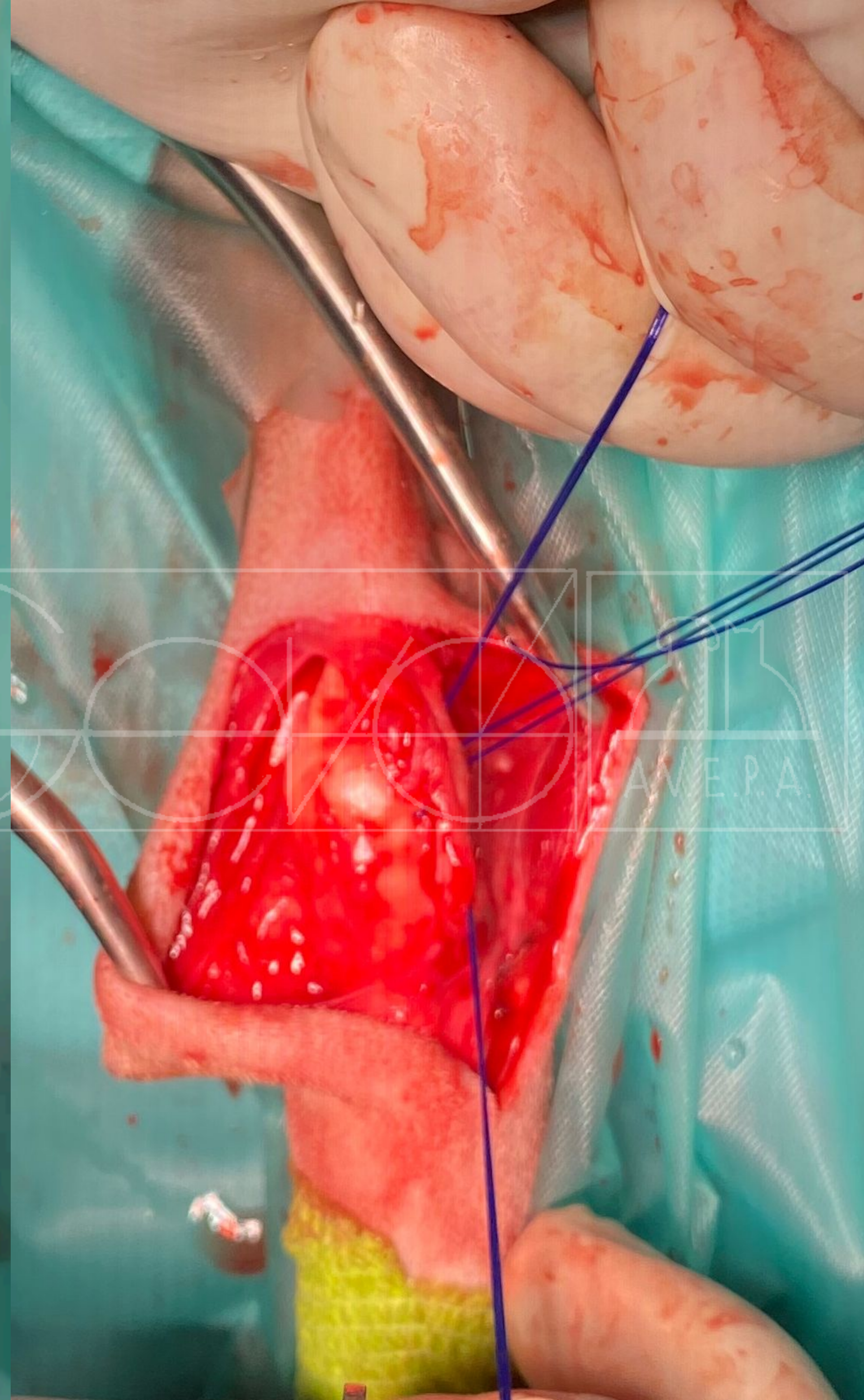
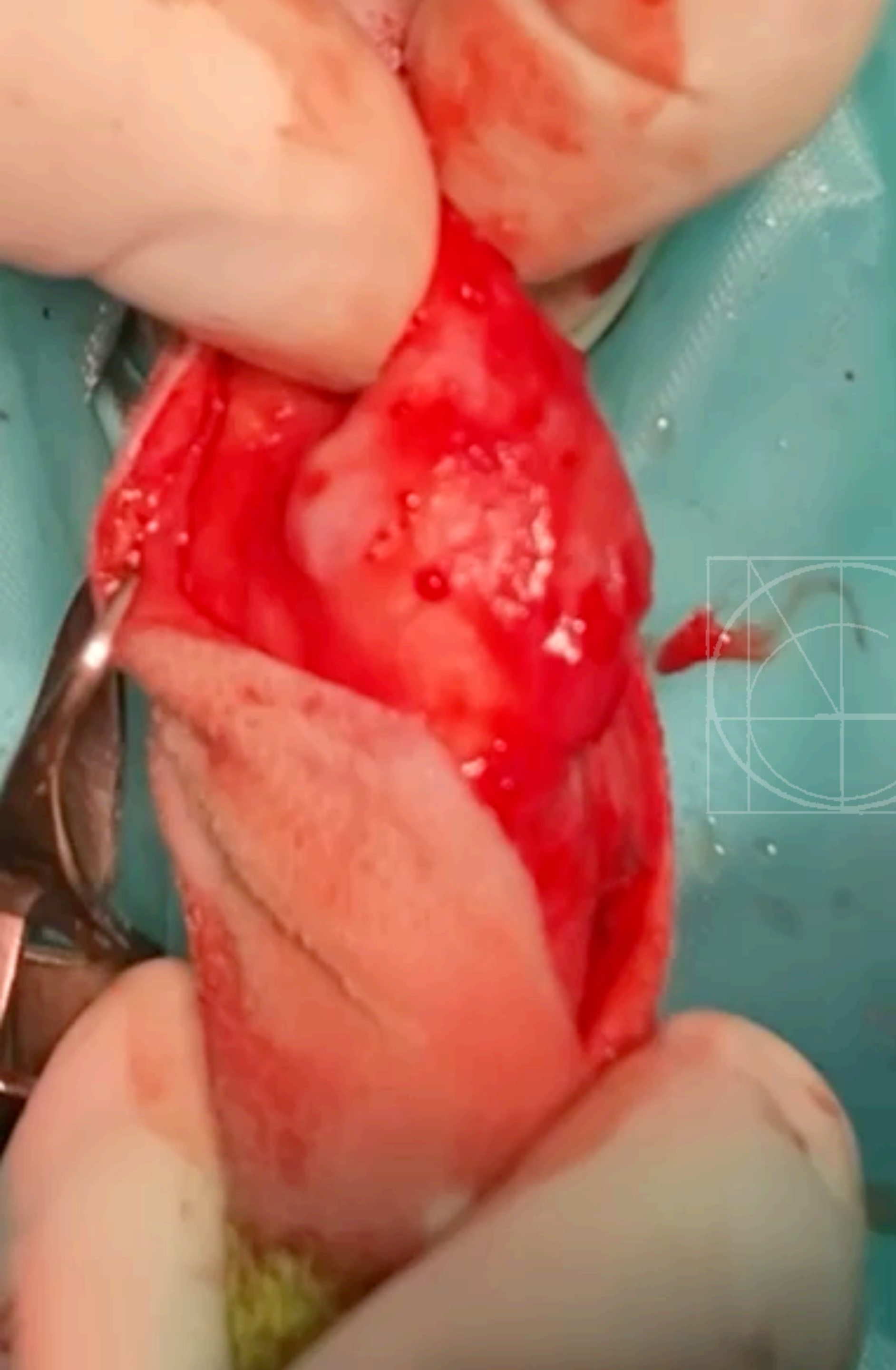
MS, Dee JF, Taylor RA. Canine sports medicine and surgery. Philadelphia, Pennsylvania, USA: Saunders; 1998. 92–99.

8. Solanti S, Laitinen O, Atroshi F. Hereditary and clinical characteristics of lateral luxation of the superficial digital flexor tendon in Shetland sheepdogs. Vet Ther 2002; 3: 97–103.

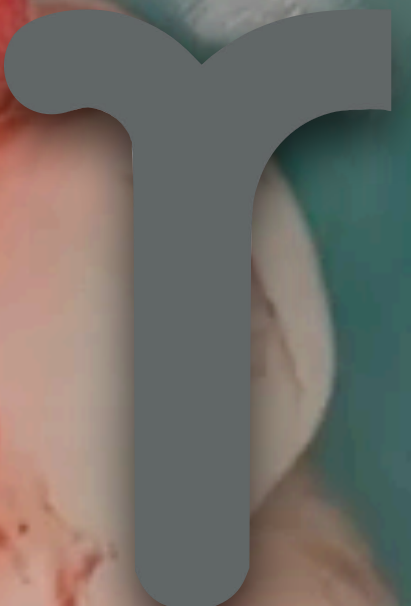9. Piermattei DL, Flo GL, DeCamp CE. Fractures and other orthopedics injuries of the tarsus, metatarsus, and palanges. In: Piermattei DL, Flo GL, DeCamp CE, editors. Handbook of small animal orthopedics and fracture repair. 4th ed. St Louis, Missouri, USA: Saunders, 2006: 661–713.

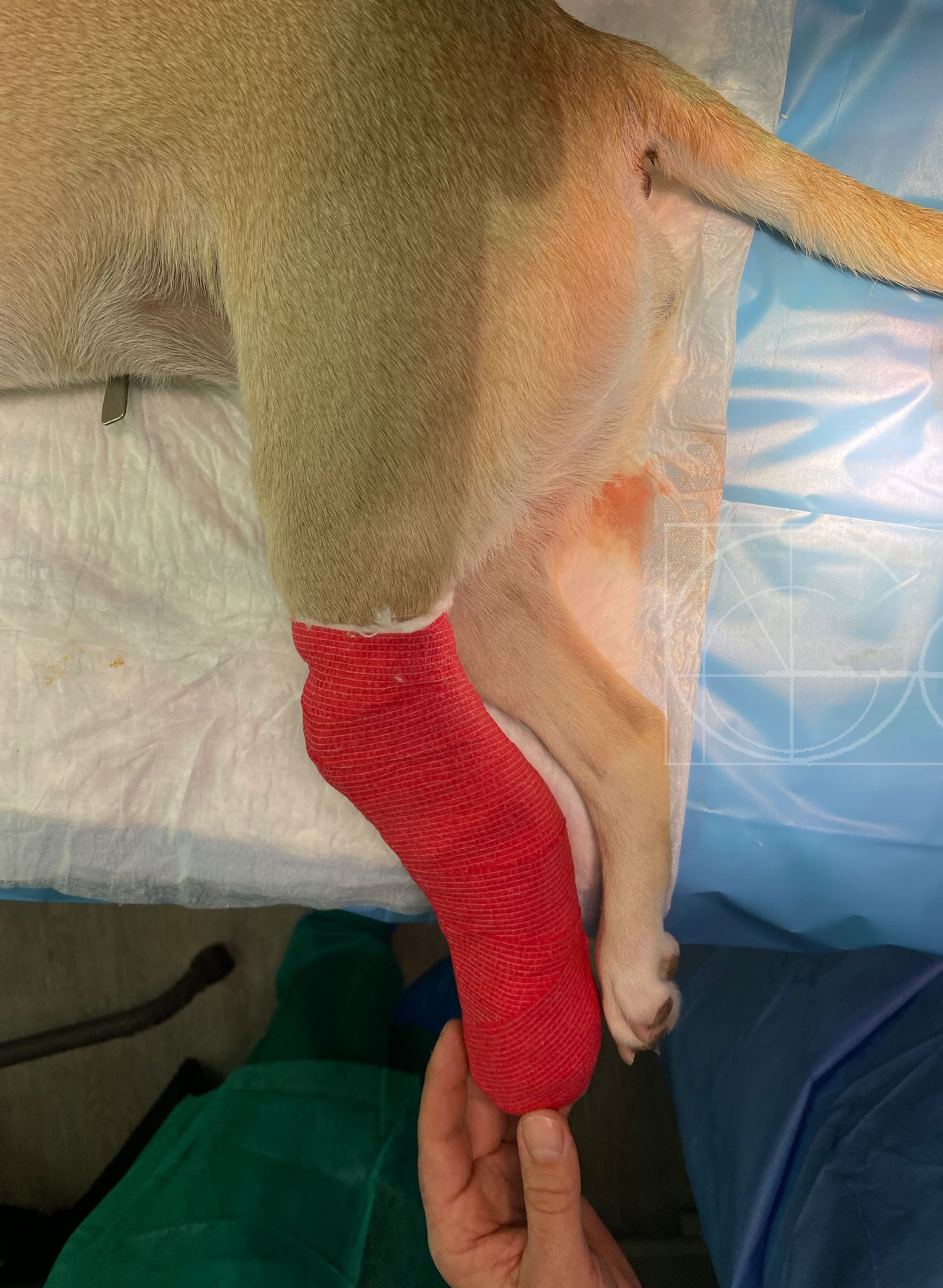10. LambCR,DuvernoisA.Ultrasonographic anatomy of the normal canine calcaneal tendon. Vet Radiol Ultra- sound 2005; 46: 32





СІМЕДІА
АВЕРРА

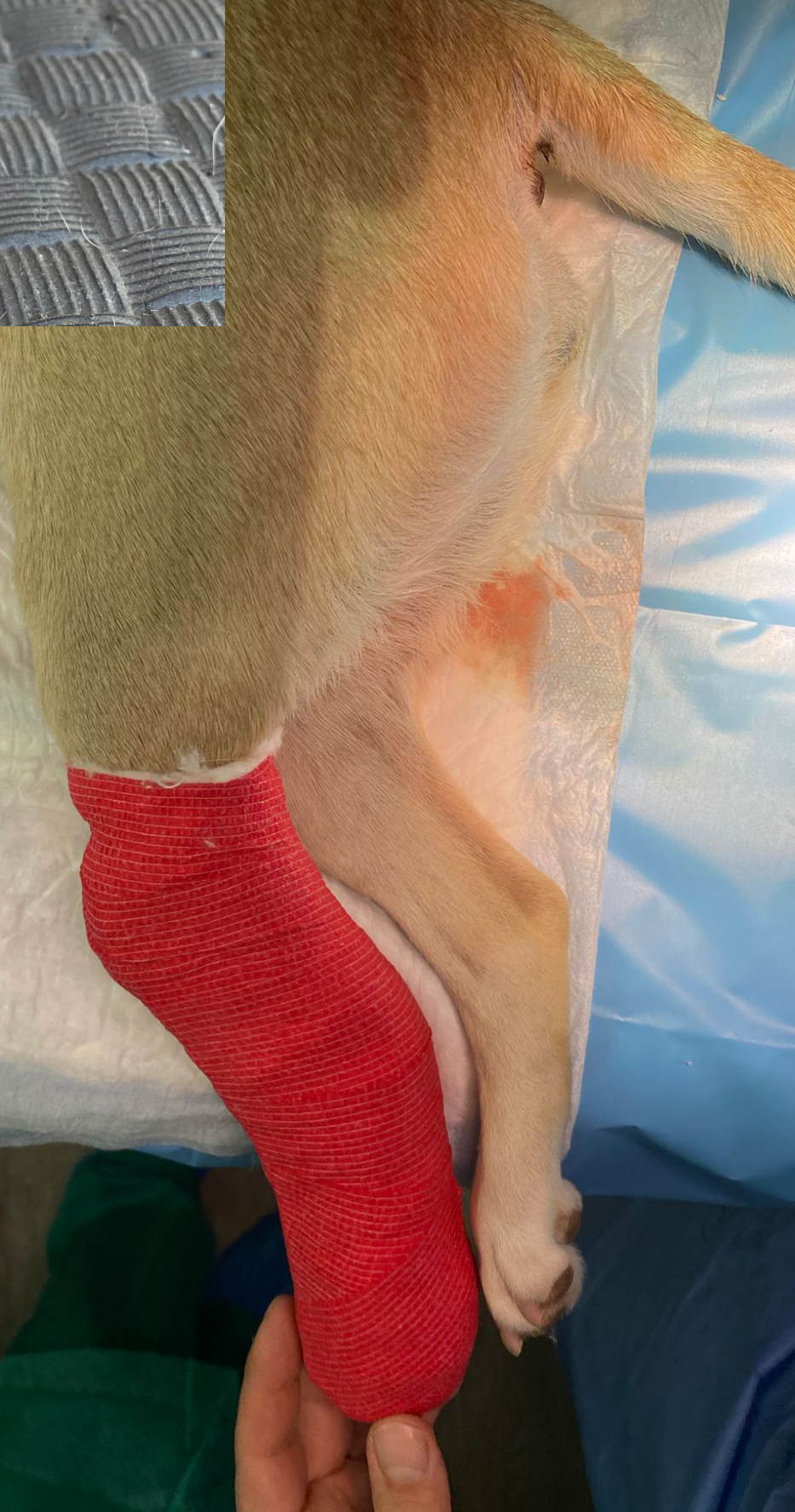
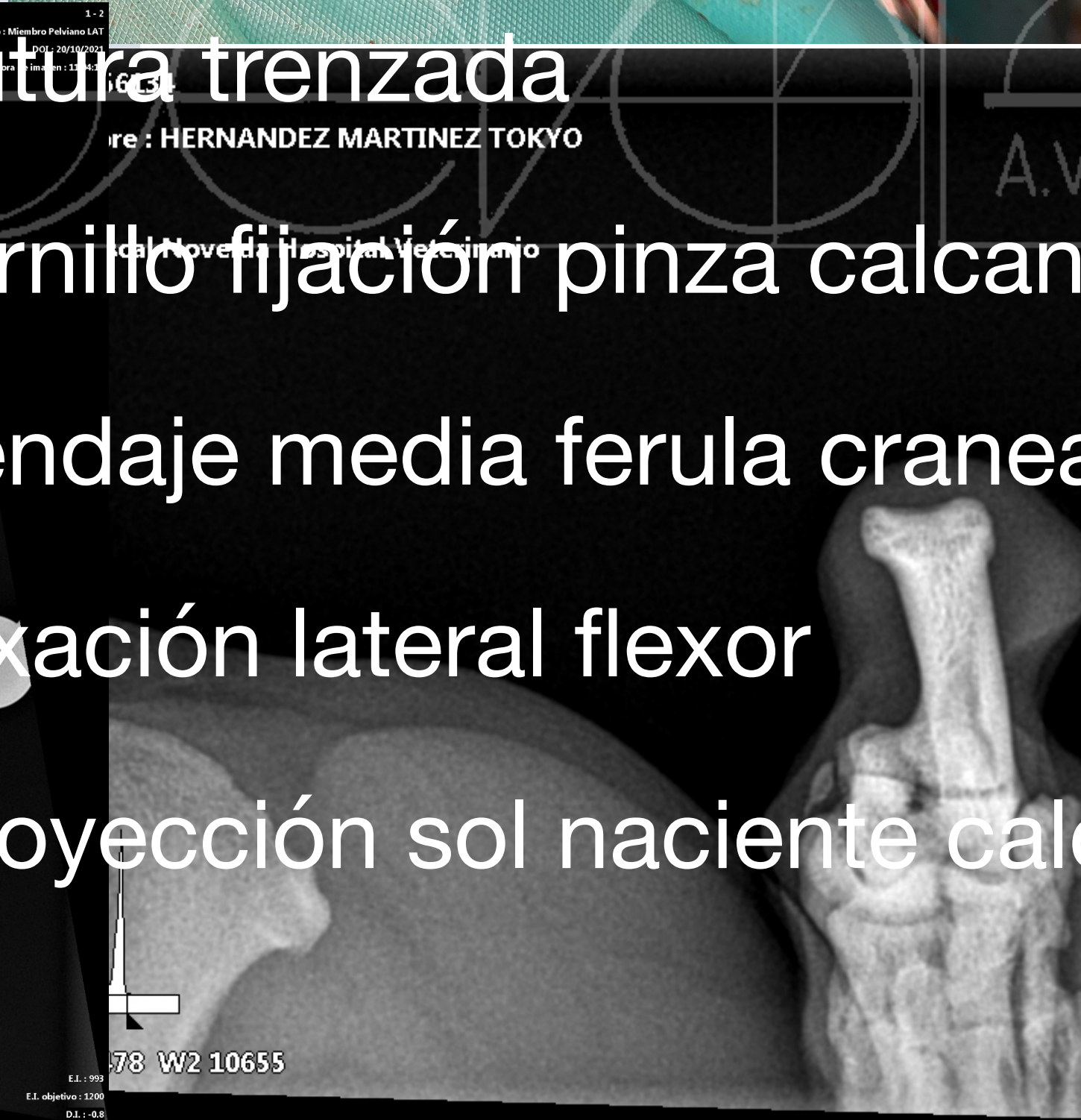
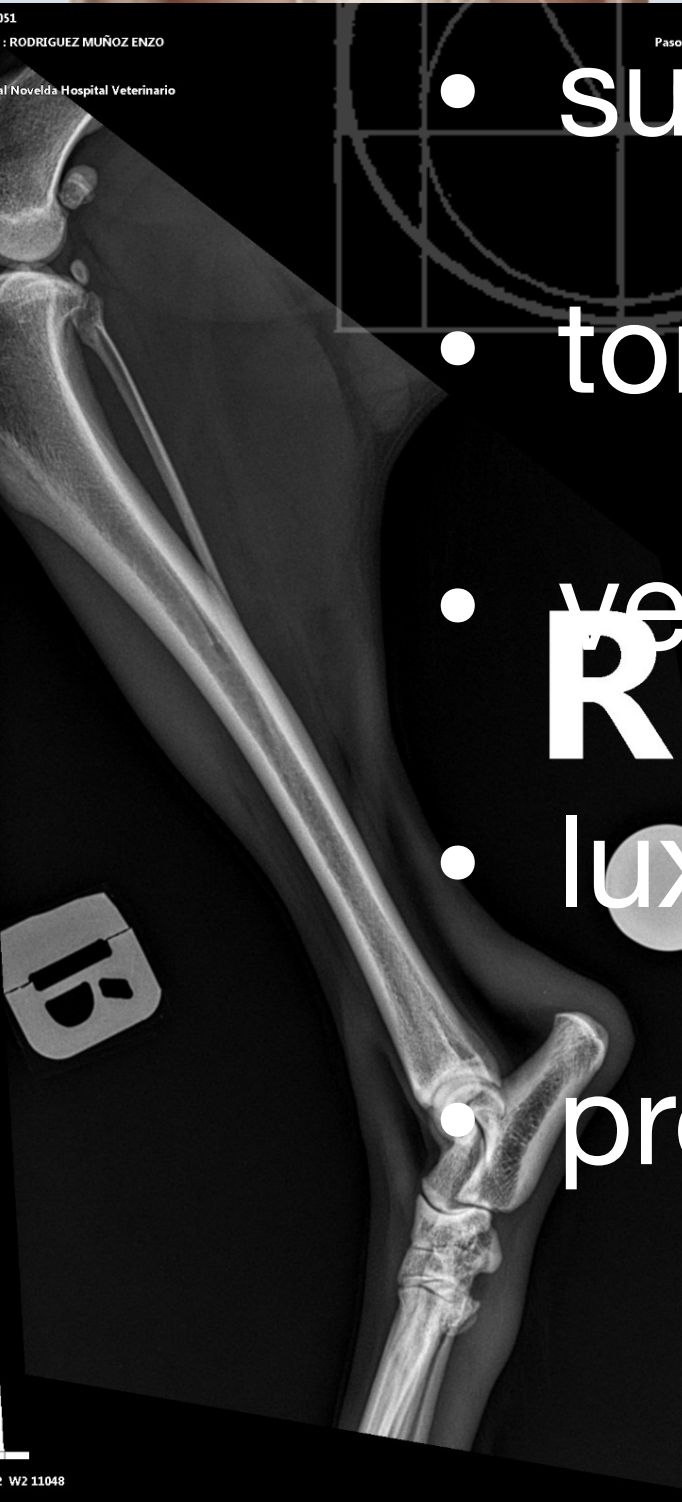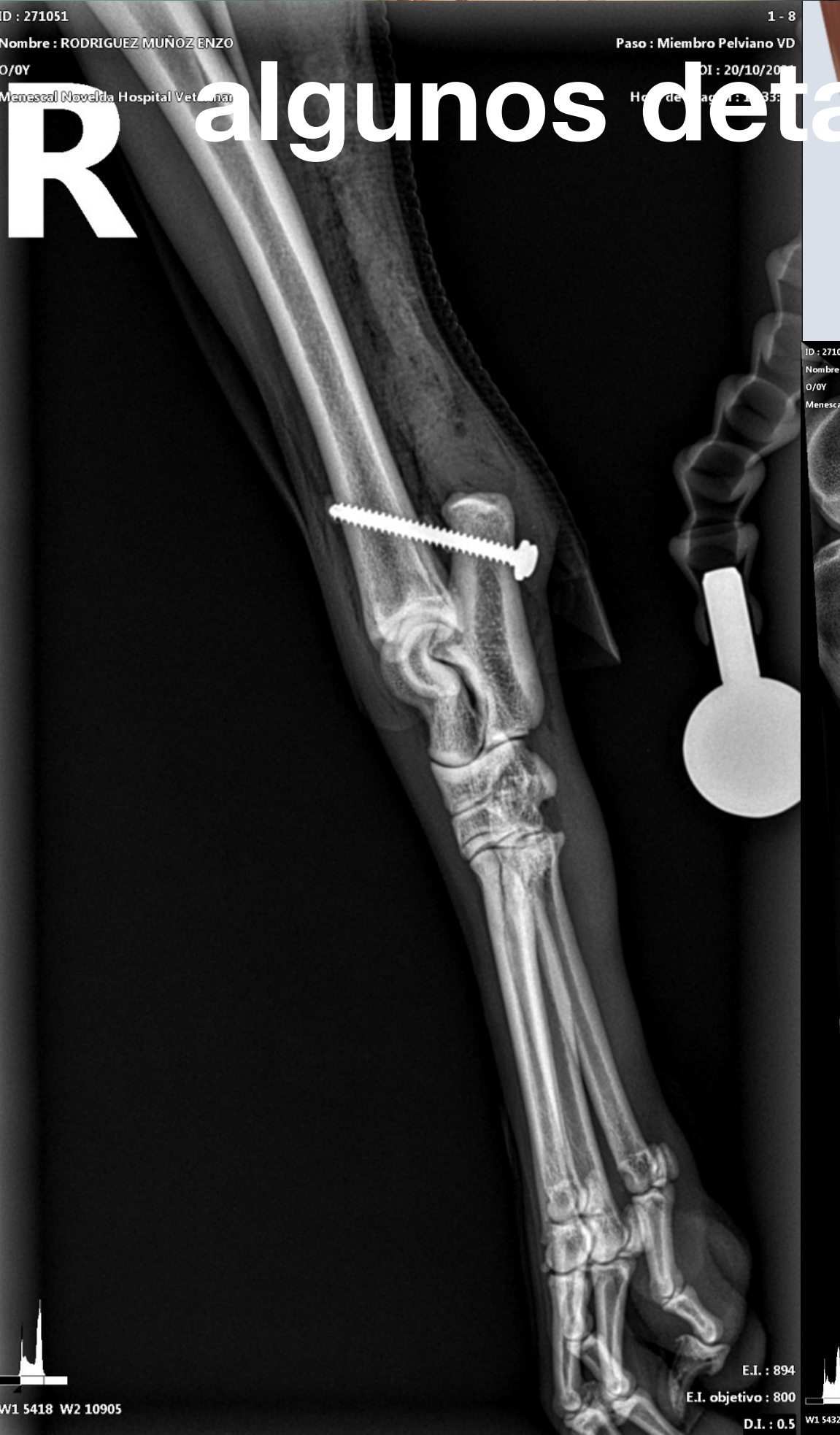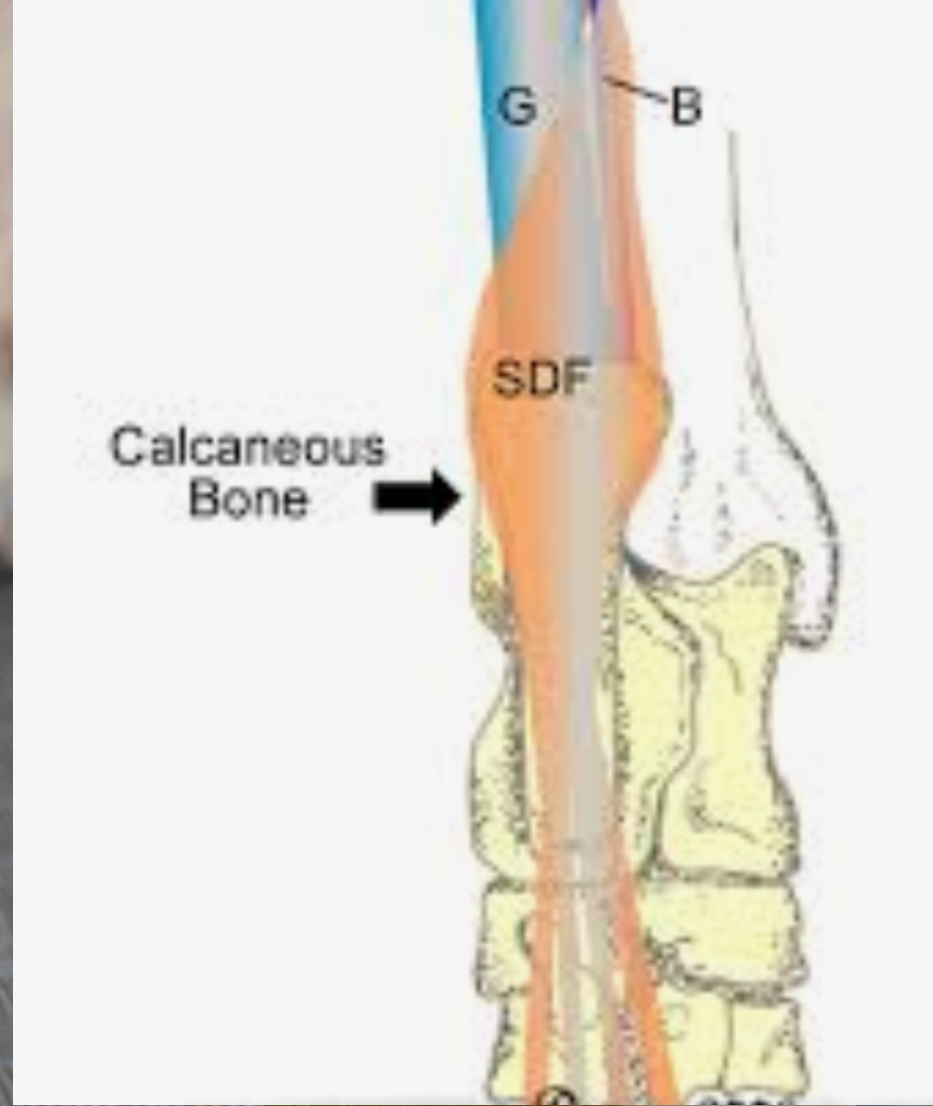
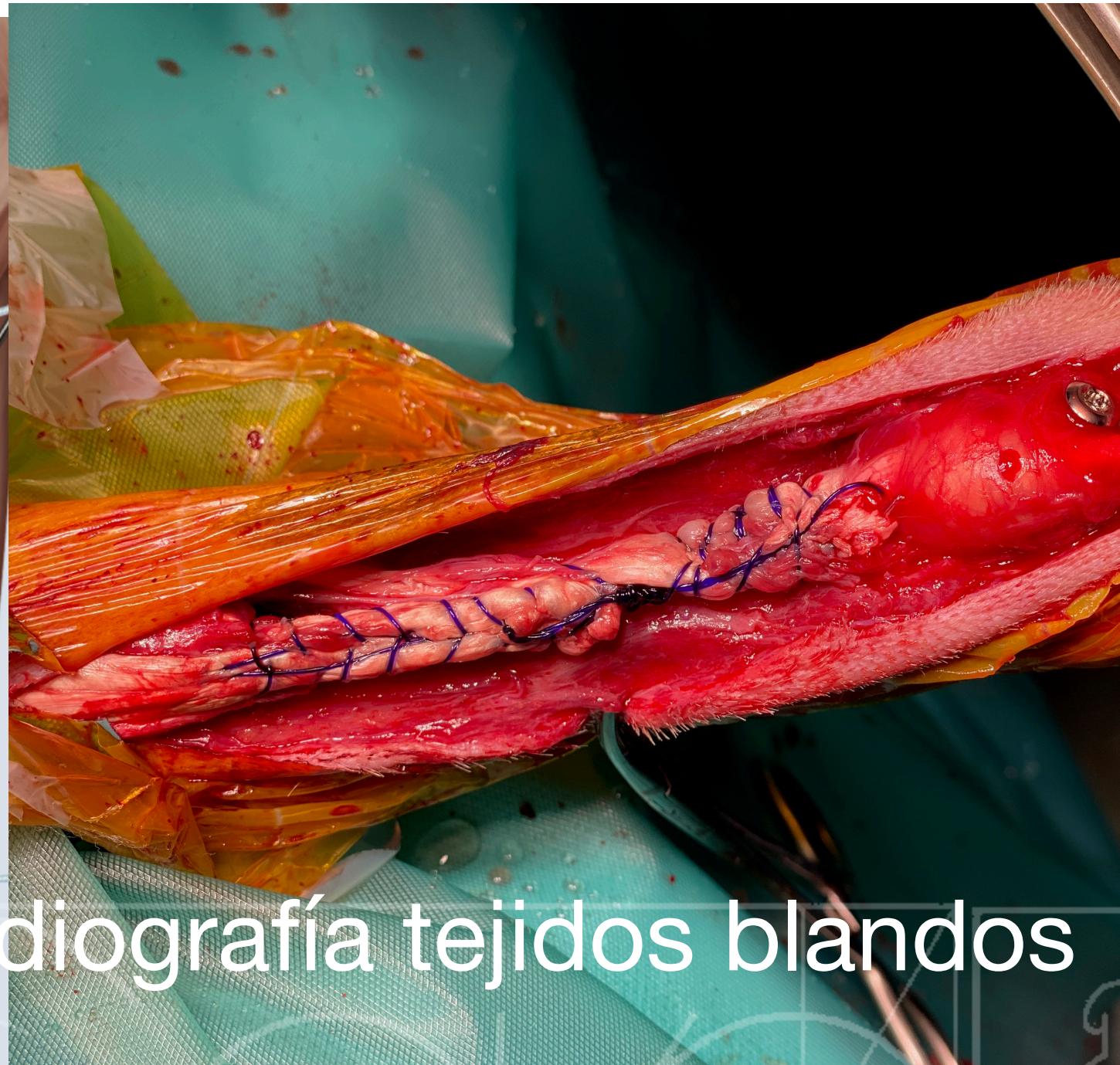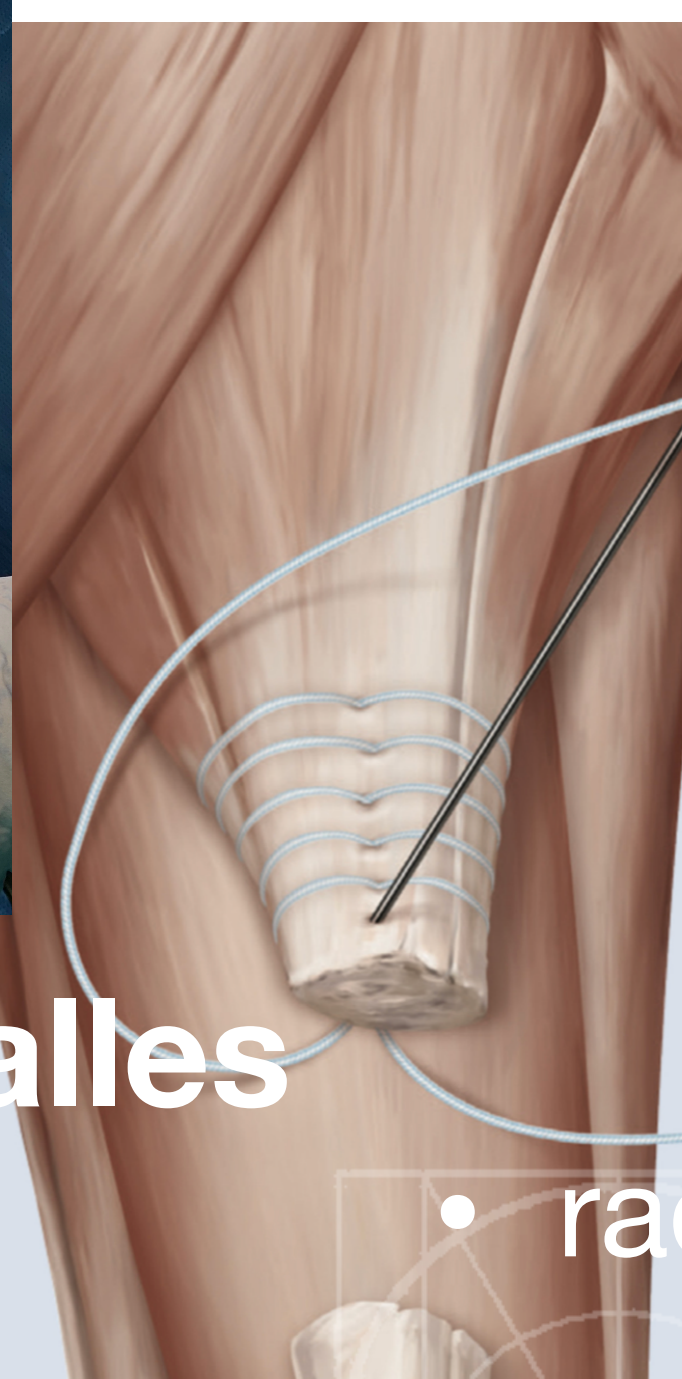
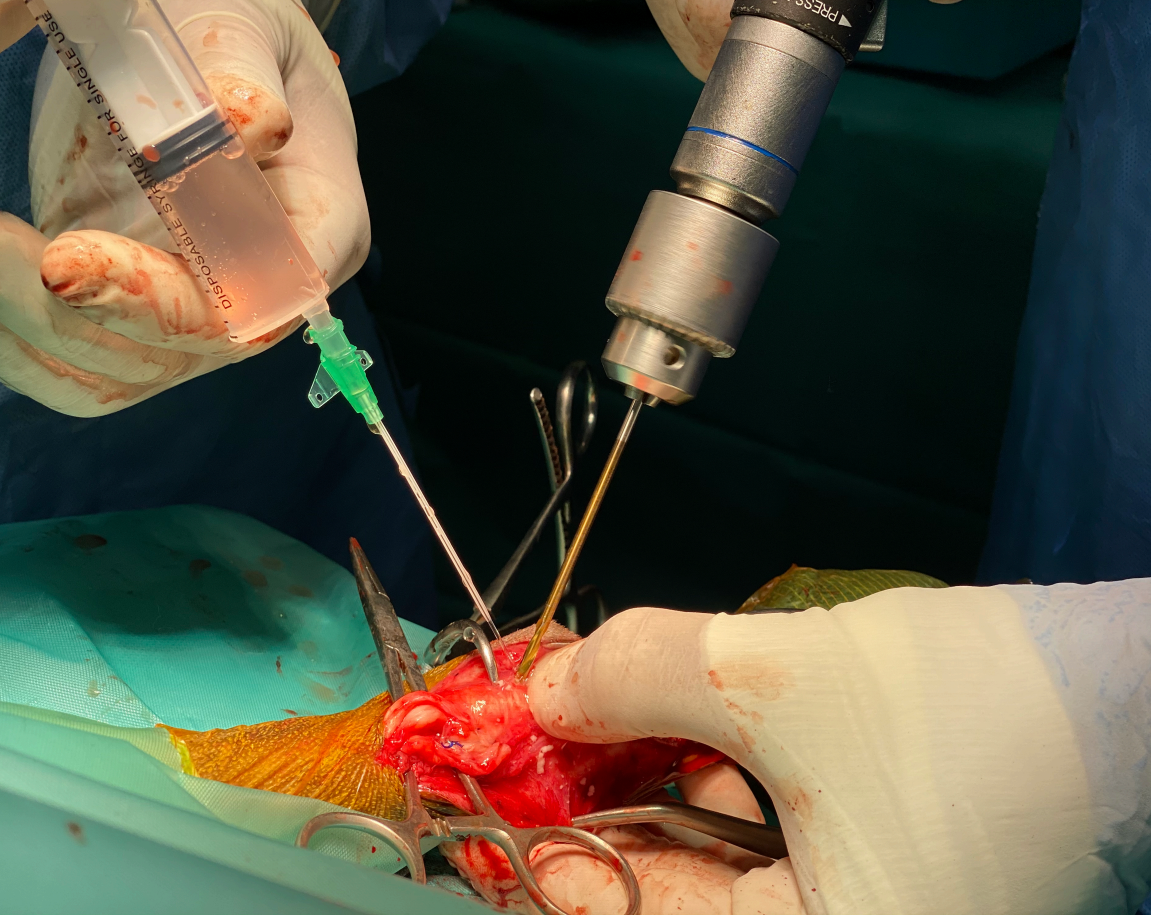




“Tokyo”
mestizo
11 kg 2
H

5 s po





R algunos detalles

- radiografía tejidos blandos
- sutura trenzada
- tornillo fijación pinza calcaneo tibial
- vendaje media ferula craneal
- luxación lateral flexor
- proyección sol naciente calcaneo